

Direct-Access Valve Replacement

A Novel Approach for Off-Pump Valve Implantation Using Valved Stents

Christoph H. Huber, MD,* Lawrence H. Cohn, MD,* Ludwig K. von Segesser, MD†

Boston, Massachusetts; and Lausanne, Switzerland

OBJECTIVES	This study validates the off-pump antegrade transventricular route for ultrasound-guided direct-access aortic valved stent implantation.
BACKGROUND	Direct-access aortic valved stent implantation offers numerous advantages over the remote-access percutaneous approach and may one day provide an alternative to surgical aortic valve replacement.
METHODS	Valved stents were implanted off-pump in 12 pigs (68.5.0 ± 7.3 kg) via direct-access transapical approach using a left-sided mini-thoracotomy and continuous ultrasonic and fluoroscopic guidance. Acute valved stent function was studied with intravascular and intracardiac ultrasound. All valved stents were tested in vitro before insertion. Macroscopic analysis was performed at necropsy.
RESULTS	In 8 of 12 pigs, valved stents were delivered to the target site over the native aortic valve leaflets without interference of coronary blood flow and with good acute valve function. Two valved stents were deployed and supra-annularly occluded the coronary orifice, leading to fatal outcome. Two valved stents dislodged into the left ventricle, one because of size mismatch and one that failed to unfold correctly.
CONCLUSIONS	Twelve pigs underwent deployment of a valved stent in the aortic position. Six valves observed for an average 4.5-h period showed satisfactory postimplantation valve function. (J Am Coll Cardiol 2005;46:366–70) © 2005 by the American College of Cardiology Foundation

The clinical feasibility of percutaneous off-pump implantation of valved stents in the right and left heart has been demonstrated (1). The remote access technique, however, is not suited to off-pump surgical aortic valve replacement (AVR) because the diseased aortic valve cannot be removed by this route, and it is preferable to remove heavily calcified native leaflets before implanting valved stents. More than a decade has passed since Andersen (2) published the principle of valved stent implantation for transluminal aortic placement. Yet introducing valved stents into the aorta remains a major experimental challenge without consensus as to design, expansion method, access, direction of delivery, or optimal deployment and positioning. We present a new concept for valved stent design and implantation using a left-sided mini-thoracotomy and direct-access-transapical approach, with the goal of developing an off-pump surgical AVR technique that might one day substitute for on-pump AVR.

PATIENTS AND METHODS

Valved stent design and in vitro testing. The valved stent custom designed for this study (Fig. 1) is based on a previously described prototype (3). The outer scaffold is constructed of three linked nitinol Z-stents that form a cylindrical structure with minimal surface coverage. The self-expanding characteristics of this valved stent eliminate the need for balloon expansion. A low-profile tissue valve is

sutured into the stent scaffold. Before implantation in vivo, all valved stents undergo static and dynamic (30 min) performance testing inside a pulsatile hydrodynamic mock loop circuit equipped with a high-fidelity tip-mounted Millar pressure transducer. Acute valve function is monitored in vivo with real-time intravascular ultrasound (IVUS) (12.5 MHz, 6-F) (Clearview, Boston Scientific Corporation, Sunnyvale, California). Criteria determining suitability for implantation include transvalvular gradient <8 mm Hg and regurgitation value ≤1°.

Animal studies. Direct-access valved stent implantation was performed in 12 pigs (68.5.0 ± 7.3 kg). All animals received humane care in compliance with the “Principles of Laboratory Animals” formulated by the National Society of Medical Research and the “Guide for the Care and Use of Laboratory Animals” prepared by the Institute of Laboratory Animal Resources and published by the National Institutes of Health. All data are expressed as mean ± SD.

Direct-access implantation technique. The jugular veins and carotid arteries are mobilized and animals fully equipped for complete invasive monitoring. An 11-F introducer (B-Braun, Medical Inc., Bethlehem, Pennsylvania) is inserted into the right femoral vein to provide intracardiac ultrasound (AcuNav) access.

A 5- to 10-cm incision is made. The sixth intercostal space is entered. A xylocaine (1.5 mg/kg) drip is started to minimize arrhythmias. Two purse-string sutures (Prolene 4-0) are placed on the left ventricular (LV) apex using the native pericardial sac for reinforcement. After heparinization (300 IU/kg), the 10-F AcuNav probe (Sequoia, operating frequencies 4.0 to 10.0 MHz, 90 cm insertion length, Acuson Corporation, Mountain View, California) is in-

From the *Division of Cardiac Surgery, Brigham and Women's Hospital, Harvard Medical School, Boston, Massachusetts; and the †Service de Chirurgie Cardiovasculaire, Centre Hospitalier Universitaire Vaudois, CHUV, Lausanne, Switzerland.

Manuscript received November 14, 2004; revised manuscript received March 25, 2005; accepted April 5, 2005.

Abbreviations and Acronyms

- AcuNav= intracardiac ultrasound
- AVR = aortic valve replacement
- CBF = coronary blood flow
- IVUS = intravascular ultrasound
- LCA = left coronary artery
- LV = left ventricle/ventricular
- RCA = right coronary artery
- RCSSI = residual coronary sinus stent index

serted into the right atrium (Fig. 2). Predeployment measurements of the aortic valve, root, and coronary ostia configuration are made with intracardiac ultrasound to avoid postdeployment interference caused by the echo-dense stent struts, a major disadvantage of transesophageal echocardiography.

LV valved stent implantation. The implant is hand-crimped to the delivery device (Fig. 3). The LV apex is punctured and a guide wire is inserted under fluoroscopic guidance. An 8-F introducer (Arrows, Reading, Pennsylvania) is advanced over the guide wire, which is placed through the aortic valve into the descending aorta. Catheter location is confirmed by AcuNav. The monorail wire-guided disposable IVUS 6-F catheter transducer (Sonicath Ultra 6, 12.5MHz Imaging Catheter, Medi-tech, Watertown, Massachusetts) is advanced for aortic road mapping. The location of the IVUS probe is monitored with AcuNav and fluoroscopy for target site identification. Three to four radiopaque markers are placed on the skin to provide additional fluoroscopic reference points at the level of the aortic annulus, end of the native leaflet in systole, sinotubular junction, and beginning of the brachiocephalic trunk. The fluoroscopic C-arm and operating table are locked into position to avoid parallaxes.

AcuNav and fluoroscopy for real-time valved stent deployment monitoring. After removing the IVUS and 8-F introducer, the valved stent delivery system is advanced over the guide wire under fluoroscopic and AcuNav guidance. When fluoroscopic and sonographic target sites reach congruency, the valved stent is deployed orthotopically over the native valve leaflets, releasing the distal end first. If the location remains unchanged, the proximal end is released.

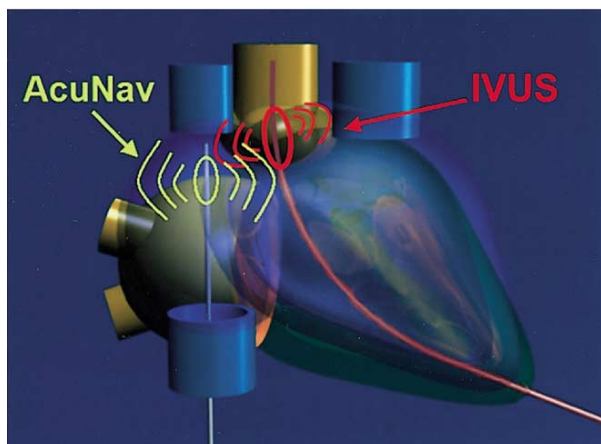


Figure 2. Navigating the valved stent through the heart with intracardiac ultrasound (AcuNav) and intravascular ultrasound (IVUS) guidance.

The valved stent is targeted to land slightly above the optimal site to ensure that the entire device can be pulled back if needed after opening the first line of the Z-stent. The self-expanding nitinol stent has a low metal-to-stent ratio with minimal contact area between the interface of the stent and aortic wall. These features increase the expansion force at the interface, creating a firm attachment to the aortic root without injuring the aortic wall. This stent design is being used clinically for aortic endovascular procedures.

The residual coronary sinus stent index. We used the residual coronary sinus stent index (RCSSI) to evaluate coronary blood flow (CBF) impairment. This index compares the flow ratio between the native coronary flow and the blood flow required to pass through the valved stent after implantation. More specifically, the RCSSI is a comparison between the coronary cross-sectional surface area and the plane defined by the valved stent and the native aortic wall (Fig. 4). Coronary diameter was measured at the termination of the sinus portion. The residual stent aortic wall plane was measured at the level of the coronary orifice. All measurements were made using intracardiac ultrasound. To calculate the index value, the distance of the stent from the aortic wall (residual gap at the level of the aortic sinus portion) is divided by the coronary diameter. Coronary

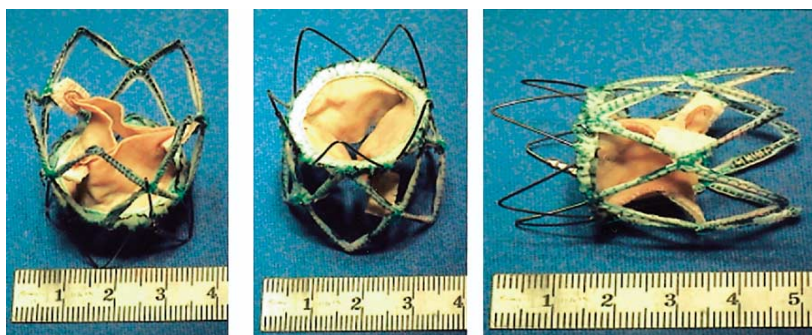


Figure 1. Valved stent used for off-pump direct-access antegrade implantation.




Figure 3. Valved stent and delivery system: the off-pump valved stent was collapsed radially and then manually loaded into a standard endoprosthetic delivery device with a maximum diameter of 9.2 mm.

blood flow impairment was not observed for index values >1 .

Outcome assessment. In vivo assessment included leaflet motion, planimetric valve orifice, RCSSI, CBF, characteristics of the left coronary artery (LCA), transvalvular gradient, regurgitation, and paravalvular leaking. After the experiments, animals were sacrificed and a macroscopic analysis was performed at necropsy.

RESULTS

In vitro study. All valved stents demonstrated good function, with a pressure gradient of 5.2 ± 2.6 and mean flow

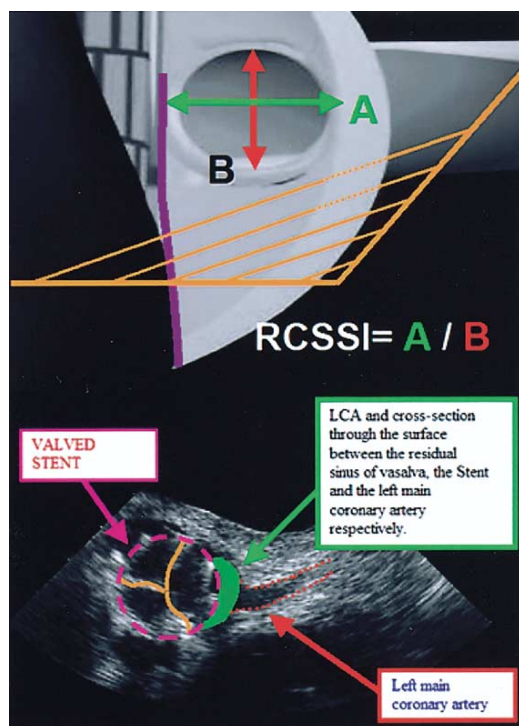


Figure 4. Intracardiac ultrasound after orthotopic valved stent implantation. LCA = left coronary artery.

rate of 4.7 ± 1.5 l/min. Intravascular ultrasound imaging exhibited full opening and closing of the pericardial leaflets in all valves. Mild paravalvular leakage was observed in 2 of 12 valved stents. No valved stent migration occurred inside the silicon valved stent chamber.

In vivo study. AcuNav measurements revealed aortic diameter 23.0 ± 2.2 mm, valve area 3.76 ± 1.3 cm², height of the native leaflets 11.4 ± 2.4 mm, depth of the coronary sinuses of Valsalva 4.2 ± 1.3 mm, height of the sinus portion 14.6 ± 1.7 mm, and diameter at the sinotubular junction 25.2 ± 2.8 mm.

Eight of 12 implanted valved stents were delivered accurately. Two were deployed supra-annularly and occluded the right coronary artery (RCA). Another two dislodged into the LV, one because of size mismatch, the other because of failure to fully deploy.

AcuNav demonstrated good leaflet motion, with full valvular opening and closing in all correctly delivered, deployed, and sized valved stents. The overall planimetric valve orifice area was 2.6 ± 0.8 cm². Of the eight correctly deployed valved stents, one had mild-to-moderate paravalvular leakage due to size mismatch and one exhibited mild regurgitation. All eight valved stents had a low transvalvular gradient of 5.3 ± 3.9 mm Hg (mean, peak-to-peak) on invasive measurement and 5.6 ± 4.7 mm Hg on noninvasive measurement.

Continuous cardiac output remained stable (5.2 ± 0.6 l/min valved stent. 4.7 ± 0.4 l/min) for the eight correctly delivered valved stents. Intracardiac color Doppler imaging revealed laminar blood flow.

Procedure time was typically 120 min (range 90 to 180 min), and duration of delivery and deployment was 4 to 6 min. The postimplantation CBF pattern using AcuNav color Doppler and M-mode (Fig. 5) indicated no signs of CBF impairment in the valved stents deployed exactly on target. Residual coronary sinus stent index was obtained to evaluate potential flow impairment in the LCA (Fig. 5). Mean distance between the coronary orifice and aortic wall was 8.1 ± 2.4 mm. Mean diameter of the LCA was 5.7 ± 1.2 mm, yielding an RCSSI value of 1.6 ± 0.5 . The postimplantation observation period was 4.5 ± 1.8 h.

Postmortem examination (Fig. 6) confirmed that 8 of 12 valved stents were correctly positioned and firmly anchored to the aortic wall. No implants showed signs of coronary obstruction. Necropsy confirmed that the two supra-annular deployments occluded the RCA. The two dislodged valved stents were found in the LV. Macroscopic analysis provided no evidence of damage to the aortic wall, signs of dissection, or hematoma. Eight valved stents were structurally sound. All were thrombus-free.

DISCUSSION

This acute animal study confirms that antegrade direct-access orthotopic aortic valve implantation via the LV apex is feasible. Recent reports show promising results with

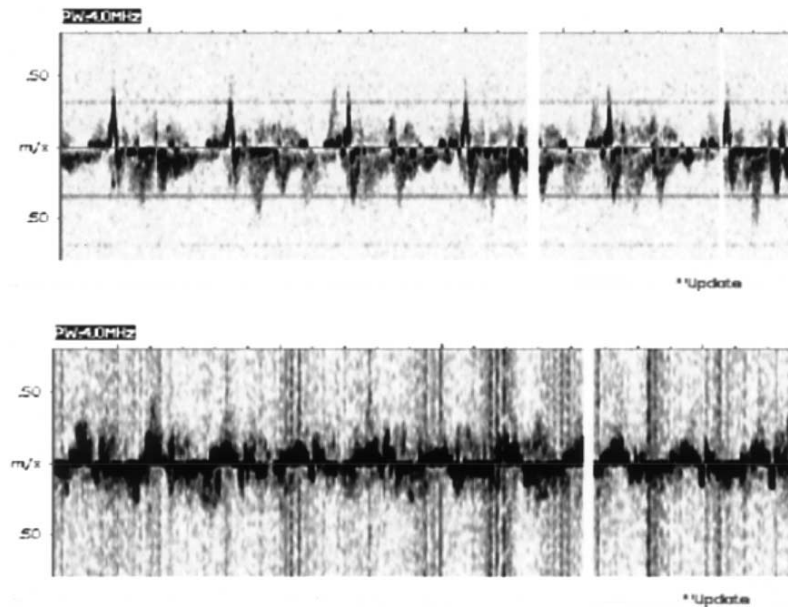


Figure 5. M-mode recordings showing stable left anterior descending flow before (**top**) and after (**bottom**) valved stent implantation.

remote access percutaneous antegrade and retrograde valved stent implantation in the pulmonary or aortic position in selected patients (1,4,5). However, the remote access technique is not a viable alternative to surgical AVR. Innovative surgical techniques are becoming increasingly less invasive (6). These innovations are likely to improve measurable parameters such as patient outcome, length of hospital stay, and perioperative mortality and morbidity, but more data are needed to establish their true benefits.

Development of an off-pump surgical AVR technique began in our laboratory in 1999 (3,7,8). Early experience with direct right ventricular access for antegrade pulmonary valved stent implantation encouraged us to develop an analog for the left heart. The advantages of direct-access via the LV apex include avoidance of the cardiopulmonary circulation, decreased distance to the target site, and ability to deliver larger devices for valve removal.

Cribier et al. (1,4) demonstrated that the antegrade approach to aortic valved stent implantation was feasible. However, mitral valve function was compromised by the transvalvular guidewire, resulting in severe mitral regurgitation in one-third of reported patients (1).

Design features for optimal implantation or replacement of the aortic valve include: 1) antegrade access through the LV apex; 2) a delivery system with directional guidance to eliminate the risk of coronary orifice obstruction; and 3) a mechanism for reloading malpositioned valved stents.

AcuNav in combination with fluoroscopy can locate the level of deployment with precision, but is not sufficient to monitor rotation of the device within the aorta before deployment. Currently, we are developing a radiopaque marker for the delivery envelope that contains the collapsed valved stent.

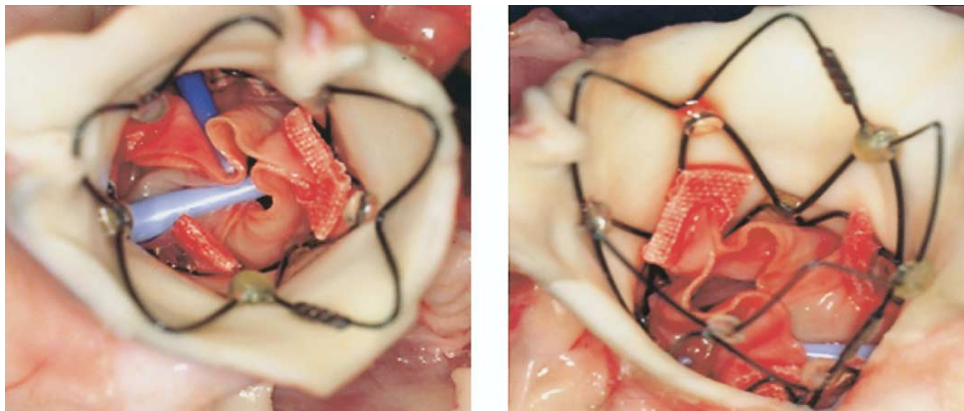


Figure 6. A valved stent in situ after antegrade off-pump implantation at autopsy. The **light blue** catheter is inside the left coronary artery orifice; the **dark blue** catheter in the right coronary artery.

Four of 12 valved stents were incorrectly placed at necropsy. Two were dislodged, one because of failure to fully expand, attributed to difficulties in collapsing and loading the device into the delivery system, and the other because an undersized valved stent was used in a larger than anticipated aortic root. Both animals remained stable during the operation, but all attempts to recover or reposition the device without going on pump failed. Only one valved stent dislodged after it was initially correctly placed. Similar difficulties have been described (9). Two valved stents were deployed supra-annularly and occluded the RCA.

No interference with CBF was found in correctly placed and deployed devices. Previous studies lack data on postimplantation CBF secondary to interference from echo-dense stent struts. AcuNav eliminated much of this interference in the present study, permitting reliable postimplantation CBF analysis. In line with previous reports (8), RCSSI was a useful indicator for absence of CBF flow interference for all index values >1 . Moreover, leaving the native leaflets in place did not cause coronary ostia obstruction. These findings conflict with other published data (9), which demonstrate a high failure rate with valved stent implants in the annular aortic position (orthotopic) consequent to flow restriction caused by the native leaflets.

Further measures to ensure the safety of valved stent aortic valve implantation and replacement include the development of embolic devices to protect the coronary orifices and aortic arch, similar to the devices used for percutaneous carotid endarterectomy or the aortic filter cannulae used in cardiac surgery. Specialized tools for remote decalcification and tissue removal are also needed. Several have been proposed, such as laser ablation, ablation chambers, or cutting catheters, but experimental data are lacking to support their feasibility. A temporary valve to support LV function during the removal/replacement interval and to overcome increased afterload caused by embolic filters and intra-aortic tools used for decalcification will also be required. Previous publications have proposed valve-tipped catheters as a temporary solution. Left ventricular

assist devices placed in the LV outflow tract, such as the Impella VAD catheter, might also work.

The necessity of placing valved stents in patients with heavily calcified aortic valves calls for new strategies and techniques such as the proposed direct-access approach. Our experimental data demonstrate that direct-access antegrade off-pump aortic valved stent implantation through the LV apex is feasible in animals with normal, noncalcified leaflets. The absence of CBF impairment or mitral valve hindrance in properly placed and sized devices makes the direct-access valved stent-based approach a promising new technology.

Reprint requests and correspondence: Dr. Christoph H. Huber, Division of Cardiac Surgery, Brigham and Women's Hospital, 75 Francis Street, Boston, Massachusetts 02115. E-mail: huberch@dr.com.

REFERENCES

1. Cribier A, Eltchaninoff H, Tron C, et al. Early experience with percutaneous transcatheter implantation of heart valve prosthesis for the treatment of end-stage inoperable patients with calcific aortic stenosis. *J Am Coll Cardiol* 2004;43:698–703.
2. Andersen H, Knudsen L, Hasenkam J. Transluminal implantation of artificial heart valves. Description of a new expandable aortic valve and initial results with implantation by catheter technique in closed chest pigs. *Eur Heart J* 1992;13:704–8.
3. Zhou JQ, Corno AF, Huber CH, Tozzi P, von Segesser LK. Self-expandable valved stent of large size: off-bypass implantation in pulmonary position. *Eur J Cardiothorac Surg* 2003;24:212–6.
4. Cribier A, Eltchaninoff H, Bash A, et al. Percutaneous transcatheter implantation of an aortic valve prosthesis for calcific aortic stenosis: first human case description. *Circulation* 2002;106:3006–8.
5. Bonhoeffer P, Boudjemline Y, Saliba Z, et al. Percutaneous replacement of pulmonary valve in a right-ventricle to pulmonary-artery prosthetic conduit with valve dysfunction. *Lancet* 2000;356:1403–5.
6. Yacoub MH, Cohn LH. Novel approaches to cardiac valve repair: from structure to function: part II. *Circulation* 2004;109:1064–72.
7. Huber CH, Nasratulla M, Augstburger M, von Segesser LK. Ultrasound navigation through the heart for off-pump aortic valved stent implantation: new tools for new goals. *J Endovasc Ther* 2004;11:503–10.
8. Huber CH, Tozzi P, Corno AF, et al. Do valved stents compromise coronary flow? *Eur J Cardiothorac Surg* 2004;25:754–9.
9. Boudjemline Y, Bonhoeffer P. Steps toward percutaneous aortic valve replacement. *Circulation* 2002;105:775–8.