

## Catheter Replacement of the Needle in Percutaneous Arteriography: A new technique

Sven Ivar Seldinger

To cite this article: Sven Ivar Seldinger (1953) Catheter Replacement of the Needle in Percutaneous Arteriography: A new technique, Acta Radiologica, 39:5, 368-376

To link to this article: <http://dx.doi.org/10.3109/00016925309136722>



Published online: 14 Dec 2010.



Submit your article to this journal [↗](#)



Article views: 406



View related articles [↗](#)



Citing articles: 81 View citing articles [↗](#)

Full Terms & Conditions of access and use can be found at  
<http://www.tandfonline.com/action/journalInformation?journalCode=iaro20>

Download by: [173.68.147.2]

Date: 09 February 2016, At: 09:29

FROM THE ROENTGEN DIAGNOSTIC DEPARTMENT (DIRECTOR: PROFESSOR KNUT LINDBLOM),  
KAROLINSKA SJUKHUSET, STOCKHOLM, SWEDEN

---

## CATHETER REPLACEMENT OF THE NEEDLE IN PERCUTANEOUS ARTERIOGRAPHY

A new technique

by

*Sven Ivar Seldinger*

The catheter method of angiography has become more popular in the past few years, as it provides the following advantages over the method of injecting the contrast medium by means of a simple needle:

- 1) The contrast medium may be injected into a vessel at any level desired.
- 2) Risk of extravascular injection of the contrast medium is minimized.
- 3) The patient may be placed in any position required.
- 4) The catheter may be left in situ without risk while the films are being developed, thus facilitating re-examination if necessary.

Until recently, however, the use of the catheter method was restricted because of the lack of a suitable flexible thin-walled catheter which could be used percutaneously. FARIÑAS, in 1941, described a method in which a urethral catheter was passed up into the aorta through a trocar inserted in the exposed femoral artery. In 1947, RADNER catheterized the exposed and ligated radial artery and performed vertebral angiography and later thoracic aortography. Since then, many authors have catheterized arteries for various purposes, by surgical exposure followed by ligation or resuturing of the artery. In 1949, JÖNSSON performed thoracic aortography after puncture of the common carotid artery by means of a blunt cannula provided with an inner sharp needle. The cannula, guided by a silver thread, was then directed downwards. Later

Briefly presented at the Congress of the Northern Association of Medical Radiology, Helsinki, June, 1952; submitted for publication, October 28, 1952.

the procedure was abandoned, partly because it was considered that the cannula might injure the aortic wall. This percutaneous method might have proved more useful if a technique for using a flexible catheter of adequate lumen had been available at the time.

The artery exposure technique of catheterization is time-consuming, troublesome and may present certain risks. The thin-walled polyethylene tube, however, makes percutaneous catheterization possible, as reported by PEIRCE in 1951, who passed in the tubing through a large bore needle. This method was suitable for aortography via the femoral artery. In the same year, DONALD, KESMODEL, ROLLINS and PADDISON, employing a similar technique, catheterized the common carotid artery in cerebral angiography. The method necessitates the use of a large bore needle which may make puncture difficult and limits its use to comparatively large arteries, hence PEIRCE's attempts to catheterize the brachial artery were disappointing. There is also extra damage to the artery and, as the hole in the artery is larger than the catheter, haemorrhage after removal of the needle may be troublesome. To prevent bleeding, the needle may be kept in situ during the investigation; this, however, increases the risk of injury to the patient during movement.

There is a simple method, however, of using a catheter the same size as the needle, and which has been used at Karolinska Sjukhuset since April 1952. The main principle consists in the catheter being introduced on a flexible leader through the puncture hole after withdrawal of the puncture needle. The details are as follows:

*Equipment.* (Supplied by A. B. Stille-Werner, Stockholm.)

- 1) A puncture needle with stilette.
- 2) A flexible rounded-end metal leader with increased flexibility of its distal 3 cm.
- 3) A polyethylene tube, of the same diameter as the needle, with an adapter for the attachment of a syringe.

26—530088. *Acta Radiologica*. Vol. 39.




Fig. 1. The equipment. The stilette is removed and the leader inserted through the needle (left) and the catheter (right).

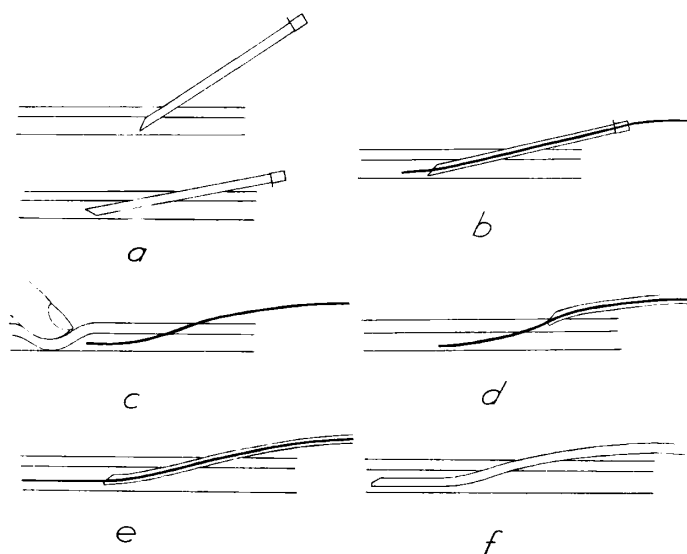


Fig. 2. Diagram of the technique used. a) The artery punctured. The needle pushed upwards. b) The leader inserted. c) The needle withdrawn and the artery compressed, d) The catheter threaded on to the leader. e) The catheter inserted into the artery. f) The leader withdrawn.

The leader should have a diameter slightly less than the bore of the needle and the catheter, so that it is capable of passing through both, and should be at least 8—9 cm longer than the latter; on the other hand it should just fit the lumen of the catheter (Fig. 1). The tip of the catheter may be cut before use as shown in Fig. 2.

*Technique* (see Fig. 2).

a) After local anaesthesia, the artery is punctured percutaneously at a relatively small angle.

After puncture it is best to rotate the needle 180° and push it a little into the artery using the bleeding as a guide to ensure that the needle remains in the artery. Puncture of arteries smaller than the femoral artery is facilitated by using an inner needle as a guide over which the outer needle is directed into the artery.

b) The supple tip of the leader is inserted a very short distance into the lumen of the artery through the needle.

c) The leader is held in place and the needle removed.

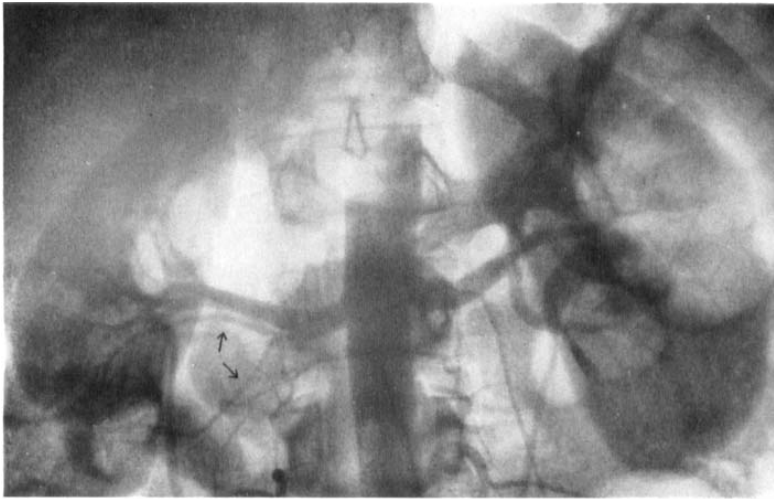

Fig. 3. Hypoplastic lower pole of the right kidney. Blood supply from two branches of a small aberrant artery. Catheter inserted through the right femoral artery with tip 2 cm below the renal arteries.

At this moment bleeding should be controlled by pressure on the artery proximal to the puncture site, because the diameter of the leader is smaller than the hole in the artery.

d) The catheter is threaded on to the leader; when the tip reaches the skin the free end of the leader must protrude from the catheter.

e) The catheter and leader are gripped near the skin through which they are inserted. The catheter enters the artery easily as an opening has already been made by the needle. The catheter and leader are pushed just far enough to ensure that the tip of the former is in the lumen of the vessel.

f) The leader is removed and the catheter directed to the level required, after good arterial bleeding through the catheter has been obtained. The unsupported catheter is usually pushed up the vessel without difficulty, but occasionally the leader must be re-introduced into the catheter in order to support it. The leader should not be passed beyond the tip of the catheter.

This technique is simpler than appears on paper and after a little practice should present no difficulties. It is important that the leader passes into the artery easily. When the tip of the catheter enters the artery, the same resistance is often felt as when puncturing is performed

# Explore Litigation Insights

Docket Alarm provides insights to develop a more informed litigation strategy and the peace of mind of knowing you're on top of things.

## Real-Time Litigation Alerts



Keep your litigation team up-to-date with **real-time alerts** and advanced team management tools built for the enterprise, all while greatly reducing PACER spend.

Our comprehensive service means we can handle Federal, State, and Administrative courts across the country.

## Advanced Docket Research



With over 230 million records, Docket Alarm's cloud-native docket research platform finds what other services can't. Coverage includes Federal, State, plus PTAB, TTAB, ITC and NLRB decisions, all in one place.

Identify arguments that have been successful in the past with full text, pinpoint searching. Link to case law cited within any court document via Fastcase.

## Analytics At Your Fingertips



Learn what happened the last time a particular judge, opposing counsel or company faced cases similar to yours.

Advanced out-of-the-box PTAB and TTAB analytics are always at your fingertips.

## API

Docket Alarm offers a powerful API (application programming interface) to developers that want to integrate case filings into their apps.

## LAW FIRMS

Build custom dashboards for your attorneys and clients with live data direct from the court.

Automate many repetitive legal tasks like conflict checks, document management, and marketing.

## FINANCIAL INSTITUTIONS

Litigation and bankruptcy checks for companies and debtors.

## E-DISCOVERY AND LEGAL VENDORS

Sync your system to PACER to automate legal marketing.