

# Journal of Parenteral and Enteral Nutrition

<http://pen.sagepub.com/>

---

## A New Nasal Bridle for Securing Nasoenteral Feeding Tubes

Jeffrey A. Meer

*JPEN J Parenter Enteral Nutr* 1989 13: 331

DOI: 10.1177/0148607189013003331

The online version of this article can be found at:

<http://pen.sagepub.com/content/13/3/331>

---

Published by:



<http://www.sagepublications.com>

On behalf of:



American Society for Parenteral  
and Enteral Nutrition

[The American Society for Parenteral & Enteral Nutrition](#)

Additional services and information for *Journal of Parenteral and Enteral Nutrition* can be found at:

**Email Alerts:** <http://pen.sagepub.com/cgi/alerts>

**Subscriptions:** <http://pen.sagepub.com/subscriptions>

**Reprints:** <http://www.sagepub.com/journalsReprints.nav>

**Permissions:** <http://www.sagepub.com/journalsPermissions.nav>

**Citations:** <http://pen.sagepub.com/content/13/3/331.refs.html>

>> [Version of Record](#) - May 1, 1989

[What is This?](#)

Downloaded from [pen.sagepub.com](http://pen.sagepub.com) by Jill Lazar on April 22, 2014

## A New Nasal Bridle for Securing Nasoenteral Feeding Tubes

JEFFREY A. MEER, M.D., F.A.C.P.

*From the Department of Medicine, Sinai Hospital of Detroit, Detroit, MI*

**ABSTRACT.** A newly designed nasal bridle and rationale for its clinical use are described. Previous nasal bridles have been shown to reduce the 40 to 60% incidence of dislodgement of nasoenteral feeding tubes. Nasal bridles, however, are still not routinely used in nasoenteral feeding of patients who dislodge their feeding tubes. Instead, percutaneous gastrostomies and parenteral nutrition are increasingly being used in these pa-

tients who may otherwise be fed adequately with a secured nasoenteral tube. The newly designed nasal bridle described herein has the advantages of easy and rapid placement. Use of this bridle can promote safer and more effective enteral feeding while avoiding the complications and cost of parenteral nutritional and gastrostomies. (*Journal of Parenteral and Enteral Nutrition* 13:331-334, 1989)

Nasoenteral feeding tube dislodgement is a common occurrence in hospitalized patients. Studies have demonstrated the incidence of this problem to range from 40 to 60%.<sup>1-5</sup> Repeated dislodgement of feeding tubes has several undesirable results: (1) feeding is delayed while awaiting proper replacement of the feeding tube; (2) there is an increased risk of aspiration of feeding solutions if the tube is partially dislodged; (3) physician and nursing staff time and effort is wasted in replacing the tube and in repeating endoscopic placement, fluoroscopy, or abdominal x-rays to confirm proper replacement of the tube; (4) there is an unnecessary increase in the use of more invasive forms of nutritional support such as gastrostomy or parenteral nutrition; (5) tube feeding solution is wasted; (6) hospital stays are prolonged, and (7) there is increased medicolegal liability as a result of the above complications. It is apparent that the current means for securing nasoenteral feeding tubes is inadequate. One means for securing feeding tubes is with the use of the "nasal bridle". This device was originally described in 1980 by McGuirt and Strout as a length of material looped around the patient's nasal septum and then secured to the feeding tube.<sup>6</sup> Their paper described the use of this device in over 100 postoperative head and neck cancer patients. They demonstrated the effectiveness and safety of the nasal bridle as there were no episodes of feeding tube removal or complications seen in these patients. Subsequent studies have further demonstrated the effectiveness and safety of the nasal bridle.<sup>7,8</sup> Additionally, a bridle "anchor" has been described as a means for increasing the effectiveness of the bridle.<sup>8</sup> It is a segment of tubing cemented around the feeding tube at the attachment site to the bridle. By tying the bridle to the tube at each end of this "anchor", slippage of the junction can be minimized.

It is surprising then, considering the high incidence of feeding tube dislodgement, that nasal bridles are used

infrequently in most hospitals. There are probably several reasons for this, mostly related to problems related to the currently used materials and techniques used for bridle assembly. These problems will be discussed later.

In this paper, a new feeding tube bridle and techniques for insertion of the device are described which will avoid the problems associated with current bridle use. Several cases are described in which the newly designed nasal bridle provided an effective solution to the problem of recurrent feeding tube dislodgement.

### DESCRIPTION OF THE DEVICE

The bridle system used in the following patients consists of an eight French polyurethane tube, 65 cm in length whose tips can be attached together by plugging the rounded tip of the bridle into the opposite hollow end of the bridle tube. (Meer Bridle System<sup>®</sup>, manufactured by ENtech, Inc., Lebanon NJ)

The bridle is secured to the feeding tube with a 4 cm width strip of adhesive-backed polyurethane tape which is positioned within the patient's nasal passageway. The polyurethane tape is a transparent, thin flap similar to the material currently used to cover intravenous catheter sites (eg, OpSite<sup>®</sup>, Smith & Nephew Inc, Columbia, S.C.). This material is resistant to loosening by nasal secretions, does not irritate mucous membranes and seems to adhere indefinitely to the feeding tube and bridle. One bridle system has the nasoenteral feeding tube preattached (Fig. 1) for simultaneous placement of the bridle and feeding tube (ENTube/Meer Bridle System ENtech, Inc.) whereas another system has a bridle alone (Fig. 2) which can be placed separately and then attached to the feeding tube with the polyurethane tape.

### INSERTION OF THE BRIDLE

Excellent detailed descriptions for insertion of jury-rigged bridles are available. (7, 8, 9) The following procedure is suggested for the insertion of the newly-designed bridle systems. Materials used for insertion of the bridle are listed in Table I.

Received for publication, September 13, 1988.

Accepted for publication, December 22, 1988.

Reprint requests: 28625 Northwestern Hwy, Suite 200, Southfield, MI 48034.




FIG. 1. Nasal bridle attached to feeding tube with polyurethane tape




FIG. 2. Nasal bridle.

TABLE I  
Materials used for insertion of the bridle

Bridle tube
Polyurethane tape
3-0 silk suture
Tongue depressor
McGill's-style forceps
Water-soluble lubricant
Rubber gloves
Face mask
Flashlight
Scissors
Optional:
10% lidocaine spray or Cetacaine spray
2% lidocaine jelly
Cotton-tipped applicator

### Procedure

1. The patient should be NPO at least 8 hr prior to placement of a bridle.

2. The patient should be in a sitting position or lying in bed with the head of the bed elevated at least 45° in order to minimize the risk of emesis. Explain the procedure to the patient.

3. Pass the nasoenteral tube through one nostril and confirm its position as desired in the usual manner. (If the preattached nasoenteral length feeding tube bridle is used, tip placement in the small bowel should first be confirmed as the tube is advanced until the bridle/feeding tube junction is just outside of the nasal columnella then this junction is advanced into the nasal passageway as the bridle is placed.)

4. In many patients bridle placement is better tolerated with the use of local anesthesia. Spray the oropharynx with topical anesthetic such as 10% lidocaine or Cetacaine.<sup>8</sup> One may also apply topical viscous xylocaine to both nasal passageways gently using the cotton-tipped applicator.

5. Pass one end of bridle through the same nostril as the feeding tube and the other end of the bridle tube through the other nostril. If using the preattached bridle, one limb of the bridle may be passed simultaneously with the feeding tube through one nostril.

6. While an assistant illuminates the oropharynx with a flashlight, depress the patient's tongue and then extract both ends of the bridle through the mouth using the McGill forceps (Fig. 3). Plug the blunt tip of the bridle into the opposite hollow tip securely (Fig. 4) and then pull slowly on one end of the bridle as indicated in Fig. 5.

7. Attach the bridle to the feeding tube by wrapping the polyurethane tape around the two tubes. Then advance the feeding tube with the attached bridle until the adhesive tape is completely inside the nasal passageway. The bridle is now looped around the nasal septum. (The loop that this forms should be loose enough so that pressure will not be constantly placed on the posterior aspect of the nasal septum as this may result in ulcera-

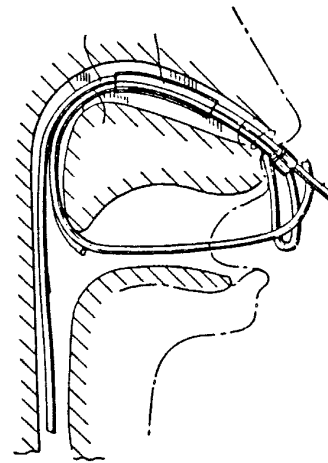


FIG. 3. Bridle and feeding tube placed in ipsilateral nasal passageway with one tip of bridle extracted through mouth.

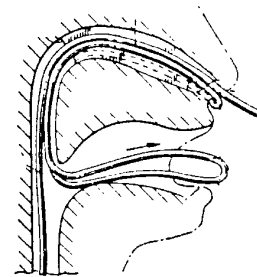


FIG. 4. Tips of bridle interconnected.

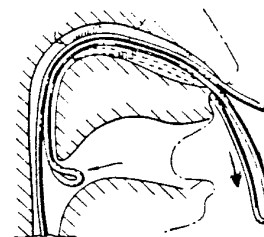


FIG. 5. Pull in direction of arrow to loop bridle around nasal septum.

tion of the latter. The loop should not, however, be large enough to allow the patient to place a small finger within it.) Tie the bridle at the nasal collumnella with 3-0 silk. Cut off excess tubing from the bridle as indicated in Fig 6.

8. The feeding tube is now securely in place with the bridle. The entire device may be completely removed by cutting the silk suture off and slowly sliding the nasoenteral tube out. The bridle will slide out right along with the feeding tube.

CASE SUMMARIES

The case summaries described in Table II illustrate some uses of the new nasal bridle and will serve as examples in the subsequent "Discussion" section.

DISCUSSION

The above cases illustrate several points with regard to the indications for the use of nasal bridles and their drawbacks. First of all, each of these patients had suffered some recent neurological insult and for this reason they were unable to swallow adequately and were periodically confused such that they inadvertently might dislodge their feeding tubes. Patients P.S. and D.B. regained the ability to tolerate oral feeding as their neurological status improved, whereas it eventually became apparent that S.C. and M.P. would not regain the ability to eat. It was difficult to determine initially, however, which patients would regain the ability to eat so that nasoenteral tube feeding was an appropriate short-term solution for maintaining nutrition without the risk or cost of parenteral nutrition or gastrostomy. These are the patients who are also very likely to dislodge their feeding tubes and are, therefore, appropriate patients for use of the

nasal bridle. Some of these patients will not regain the ability to tolerate oral feeding and in these patients it is probably more appropriate to place a feeding gastrostomy. It is, however, usually not possible to determine which patients will or will not recover their ability to take oral feeding and it is appropriate to use a nasoenteral feeding tube secured with a bridle for a period of 2 to 6 weeks until this can be determined with more certainty. Since PEG (percutaneous endoscopic gastrostomy) tubes can be placed relatively easily in many patients, there may be a tendency to place PEG's initially in these patients. Placement of PEG tubes, however, is costly and may occasionally result in significant complications.<sup>10,11,12</sup> Such complications have included local infections, fistulae, peritonitis and, rarely, death due to sepsis or respiratory failure. Parenteral nutrition, too, is both costly and may lead to significant complications such as pneumothorax, catheter sepsis and subclavian vein thrombosis. It is therefore generally accepted that "when the gut works, use it." As illustrated in some of these cases, many of these patients do not need to be exposed to the increased morbidity of this procedure as they will regain their ability to take oral feeding within a few weeks.

Another group of patients in whom bridle use has been shown to be useful is in postoperative head and neck cancer patients.<sup>6</sup> Replacement of a dislodged feeding tube in these patients is quite hazardous due to the risk of disrupting fresh suture lines when the tube is passed.

In view of the high incidence of nasoenteral feeding tube dislodgement, one would expect bridles to be used frequently. This, however, has not been the case in most hospitals. The following are four basic reasons for the reluctance to use bridles along with a discussion on how the new bridle and the above technique for bridle placement avoids these problems:

1. The procedure for placing the currently used jury-rigged bridles is time-consuming, tedious, cumbersome and can be quite difficult in an uncooperative patient. Insertion time for the new bridles, however, is much less because: (1) the interconnecting tips eliminate the time-consuming and technically difficult step of tying the tips of the bridle together after they have been extracted from the mouth. (2) preconnection of the bridle to the feeding tube eliminates another time-consuming step. Alternatively, the use of adhesive polyurethane tape is quicker than suture material for securing the feeding tube to the bridle, (3) the availability of a bridle kit decreases the time required to gather supplies, (4) adequately anesthe-

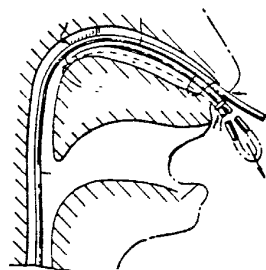


FIG. 6. Bridle and feeding tube in place.

TABLE II  
Case summaries

Patient/age/sex	Diagnosis	Reason for tube feeding	Number of tubes dislodged previously	Min to place bridle	Complications	Number of days bridle in place	Reason for tube dislodgement
AS 68 M	CVA	Dysphagia	1	10	None	>35	Not dislodged
PS 64 F	CVA	Dysphagia	3	12	None	4	Began oral feeding
SC 82 M	CVA	Dysphagia	2	35	Nasal ulcer	17	Changed to PEG tube
MP 68 F	CVA	Dysphagia	2	20	None	14	Inadvertent
DB 58 F	Dementia sepsis	Anorexia	5	15	None	17	Began oral feeding

tizing the oropharynx and nasal choanae will enhance patient compliance during the procedure and allows the procedure to progress without patient interference.

In the above cases, the time required for insertion of the bridles varied from 10 min to as long as 35 min. In the author's experience, bridle placement rarely takes more than 15 min. If one calculates the amount of time required to replace a feeding tube two or three times, it will be obvious that the use of bridles will save a substantial amount of time and effort for physician and nursing staff over the long run. If the tube tip must be placed in the small bowel via fluoroscopy or endoscopy and confirmed by x-ray even greater amounts of time will be saved.

2. Another reason that bridles are not yet commonly used is that there is concern over potential complications of the bridle (eg, fracture or ulceration of the nasal septum) and patient discomfort during insertion of the bridle (eg, gagging). Although fracture of the nasal septum has never been reported with bridle use, it is reasonable to be concerned about this complication especially in elderly, osteoporotic patients. It is likely, however, that it is not the strength of the bridle that secures the feeding tube but rather the immediate discomfort created when the patient pulls even gently on the feeding tube bridle that actually prevents tube dislodgement. For this reason, it is unlikely that one will have to secure most bridles with more than a couple loops of 3-0 suture. Those patients who pull hard enough to break the sutures should probably have their tubes secured by other means or have PEG's placed.

The patient A.S. experienced a minor complication from his bridle as he developed a pressure ulcer on the nasal columnella. This is easily remedied by loosening the bridle loop slightly.

With regard to patient discomfort during the procedure, as discussed previously, this problem can be minimized with adequate topical anesthesia and as expertise is gained with the procedure.

3. Some people feel that a bridle looks uncomfortable or undignified but patient acceptance has never been a problem. When patients' families understand the risks and benefits of bridles *vs* the risks of repeated tube dislodgement or other invasive forms of feeding, they are usually agreeable to having the bridle used. It is certainly less uncomfortable and less undignified to place a bridle than to have feeding tubes replaced multiple times.

4. Lastly, there are several technical problems with the current jury-rigged bridles. One is that when the feeding tube is secured to the bridle by the currently-used methods, an adept patient can pull the feeding tube out by pulling on the tube proximal to the site at which it is secured to the bridle. This problem is avoided in the new bridle by securing the feeding tube to the bridle for a distance of at least 4 cm and by positioning this junction

such that it is well within the nasal passageway. Another problem is that the feeding tube can slip through the sutures which secure it to the bridle and, at times, the feeding tube may become compressed and its lumen obstructed by the suture which ties the tube to the bridle. The new bridle avoids this problem by securing the feeding tube to the bridle with a strip of polyurethane tape such that obstruction of the tube lumen and slippage of the feeding tube is impossible.

#### CONCLUSIONS

Nasal bridles have been previously demonstrated to be safe, effective means for securing nasoenteral feeding tubes for patients who are likely to dislodge their feeding tubes and for postoperative head and neck cancer patients in whom even a single episode of tube dislodgement constitutes a major problem due to difficulties with reinserting nasoenteral tubes. With the use of adequate assistance and proper instruments, topical anesthetics and the newly designed bridle, one may avoid many of the shortcomings of the currently used jury-rigged bridles.

#### ACKNOWLEDGMENTS

The author wishes to thank Dr. Melvyn Rubenfire for his comments on the manuscript.

#### REFERENCES

1. Jeffers SL, Dorr LA, Meguid MM: Mechanical complications of enteral nutrition: prospective study of 109 consecutive patients (Abstr). *Clin Res* 32:233A, 1984
2. Keohane PP, Attrill H, Jones BJM, et al: Limitations and drawbacks of fine bore nasogastric feeding tubes. *Clin Nutr* 2:85, 1983
3. Vasquez R, Craig R, Slas T: Performance and acceptability of Entriflex feeding tube with hydromer lubricated lumen and mercury weight and placement stylet. *Nutr Support Serv* 7:9-11, 1981
4. Crocker K, Krey S, Steffee W: Performance evaluation of a new nasogastric feeding tube. *JPEN* 1:80-82, 1981
5. Meer J. Inadvertent dislodgement of nasoenteral feeding tubes: incidence and prevention. *JPEN* 11:187-189, 1987
6. McGuirt WF, Strout JJ: Securing of intermediate duration feeding tubes. *Laryngoscope* 90:2046-2048, 1980
7. Barrocas A, Jastram C, St. Romain C: The bridle: increasing the use of nasoenteric feedings. *Nutr Support Serv* 2:8-10, 1982
8. Levenson R, Dyson A, Turner W: Feeding tube anchor. *Nutr Support Serv* 5:40-42, Aug 1985
9. Forlaw L, Chernoff R: Enteral delivery systems. IN *Clinical Nutrition Vol I: Enteral and Tube Feeding*, Rombeau J, Caldwell M (ed). W.B. Saunders, Philadelphia, 1984, pp 231-233
10. Torosian M, Rombeau J: Feeding by tube enterostomy. *Surg Gynecol Obstet* 150:918-927, 1980
11. Ponsky JL, Aszodi AA: Percutaneous endoscopic jejunostomy. *Am J Gastroenterol* 79:113-116, 1980
12. Kirby DF, Craig RM, Tsang T, et al: Percutaneous endoscopic gastrostomies: a prospective evaluation and review of the literature. *JPEN* 10:155-159, 1986