

**"HOW I DO IT" — HEAD AND NECK  
A Targeted Problem and Its Solution**

**SECURING OF INTERMEDIATE DURATION FEEDING TUBES.\***

W. FREDERICK MCGUIRT, M.D.,

and

JOHN J. STROUT, M.D.,

Winston-Salem, NC.

**INTRODUCTION.**

It is well recognized that nutritional support and a positive nitrogen balance are essential to wound healing and the rebuilding of tissue. In the preoperative and postoperative management of many patients with head and neck cancer, nasogastric feedings are necessary for several weeks to ensure that nutrition is adequate. The indwelling nasogastric tube remains the preferable method for short to intermediate duration feeding (3-21 days) in the patient with an intact gastrointestinal tract. Cervical cutaneous esophageal feeding tubes may be appropriate for longer-term care, but are not usually necessary for the postoperative head and neck cancer patient and may, in fact, result in formation of a permanent cutaneous esophageal fistula after they are removed.

The major drawback to an indwelling nasogastric feeding tube has been its premature, accidental removal. To replace this tube into or through a fresh operative field is risky, and one does not do it without reservation due to the possibility of traumatizing the suture line with possible subsequent infection, wound breakdown, or fistulization. Routine taping and pinning of the tube or including the tube within encircling dressings has not prevented patients from deliberately and nursing assistants from accidentally removing the tube. Actual suturing of the tube through the nasal columella has been done, but the chronic pull on the columella and the constant nasal secretions may cause local infection and significant damage to the soft tissue and cartilage of the columella. In fact, we have seen two cases where the securing suture, constantly tugging in an irritated area, sawed the columella in two.

To prevent those problems, we use the following method of securing nasogastric tubes postoperatively in patients with head and neck cancer and in all patients who tend to dislodge their feeding tubes repeatedly. We have used this method in over 100 patients and in none has there been a premature extubation or a complication.

**THE TECHNIQUE.**

The nares are first decongested with a topical spray. For the awake patient, we prefer 5% cocaine solution, which both decongests and anesthe-

\*From the Section on Otolaryngology of the Department of Surgery, Bowman Gray School of Medicine of Wake Forest University, Winston-Salem, NC.

Send Reprint Requests to W. Fred McGuirt, M.D., Section on Otolaryngology, Bowman Gray School of Medicine, Winston-Salem, NC 27103.

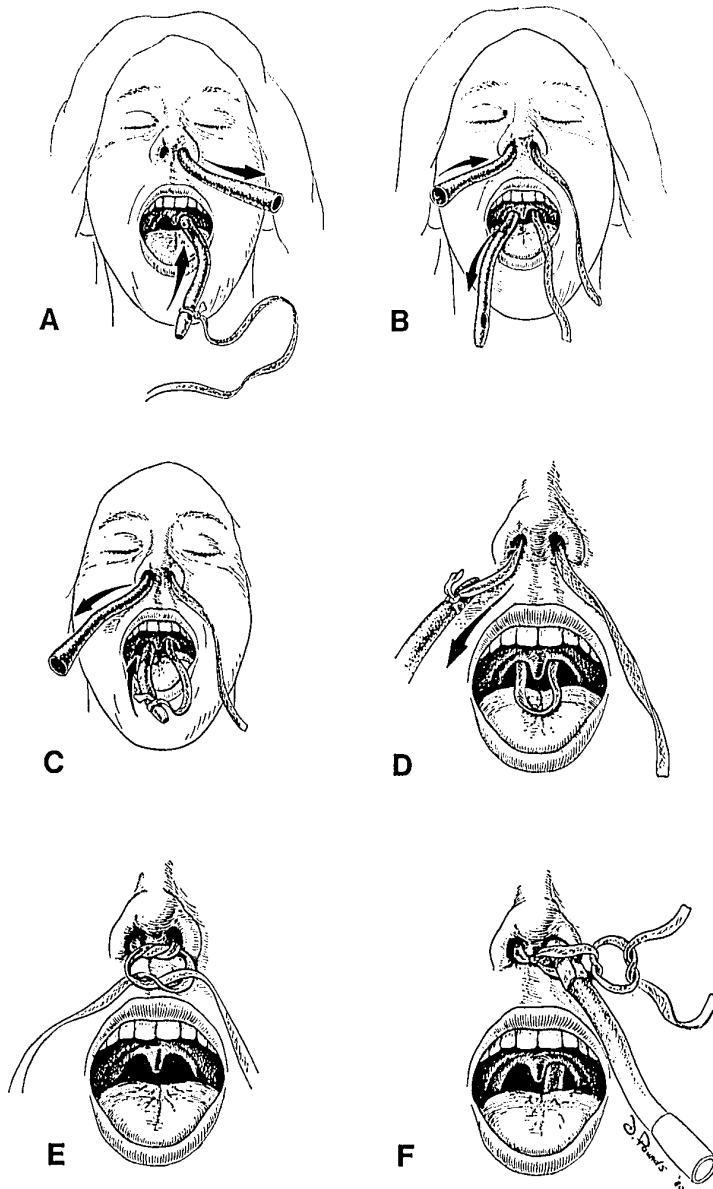


Fig. 1-A. Nasogastric tube with umbilical tape attached is removed retrogradely. 1-B. Nasogastric tube is passed through other naris and brought out the mouth. 1-C. Umbilical tape is tied to the tip of tube and tube is removed retrogradely (1-D). 1-E. Tape is tied around columella with square knot. 1-F. Nasogastric tube is secured with second square knot.

tizes. The more widely patent naris is the one selected for passage of the tube. Initially, a small red rubber catheter is passed through one naris. The tip of the catheter is grasped in the oropharynx and brought outside the mouth so that a 60-cm length of one-quarter-inch umbilical tape can be tied to it. The catheter is then removed retrogradely (Fig. 1-A), a maneuver that leaves the tape in the naris. The tape is untied and the catheter is passed through the other naris so that its tip can again be grasped and brought outside the mouth (Fig. 1-B). The oropharyngeal end of the tape is tied to the tip of the catheter, and the catheter is again removed retrogradely (Fig. 1-C). In that manner, a loop of umbilical tape has been brought to lie around the nasal septum with a free end hanging externally from each naris (Fig. 1-D). The umbilical tape is then tied loosely in a square knot over the columella (Fig. 1-E), with approximately 5 mm. of slack left in the tape around the nasal septum. In a conventional manner, the nasogastric tube is then passed into the stomach through the pre-selected naris. A small amount of benzoin is painted on the tube where it enters the nose, and over that a small piece of one-half-inch cloth tape is placed. The ends of the umbilical tape are then tied securely in a square knot over the cloth tape to secure the nasogastric tube against the previously-tied square knot over the columella (Fig. 1-F).

This tube cannot be removed unless the umbilical tape is cut. The slight degree of slack in the encircling umbilical tape, the width of that tape, and the fact that the pressure point on the posterior nasal septum lies over bone, all tend to prevent tissue erosion. The small amount of slack or "give" in the system also allows a change in pressure to be transmitted to the posterior septum when the tube is tugged down. That change in sensation reinforces to the patient the idea that the tube is not to be removed.

In summary, a method to secure a nasogastric tube for intermediate-duration tube feeding is presented. It is especially appropriate during the post-operative care of a patient with head and neck cancer, when reinsertion of the tube carries the risk of rupture of a suture line. To date, in over 100 patients, we have seen no complications and no premature extubations resulting from the use of this technique.

---

#### THE NATIONAL SYMPOSIUM ON HAIR REPLACEMENT SURGERY.

The National Symposium on Hair Replacement Surgery — co-sponsored by the American Academy of Facial Plastic and Reconstructive Surgery and The American Society for Dermatologic Surgery will meet on February 6-8, 1981 at Ramada Inn, Beverly Hills, Los Angeles, California.

This seminar will be an intensive practical course including lectures, panel discussions, workshops and videotapes covering all aspects of hair replacement for the beginner and experienced surgeon.

For additional information contact: Richard Fleming, M.D., or Toby Mayer, M.D., Course Directors, at 9730 Wilshire Blvd., Ste. 216, Beverly Hills, CA 90212.