

□ Albert Barrocas, MD, FACS, Medical Advisor, Nutritional Support Service, Pendleton Memorial Methodist Hospital, Clinical Associate Professor, Department of Surgery, Tulane University School of Medicine, Adjunct Associate Professor, Department of Nutrition, Tulane University School of Public Health and Tropical Medicine; Charles Jastram, RPh, Clinical Pharmacist, Nutritional Support Service, Pendleton Memorial Methodist Hospital; Clare St. Romain, RD, Clinical Dietitian, Nutritional Support Service, Pendleton Memorial Methodist Hospital, New Orleans, Louisiana 70127

The Bridle: Increasing the Use of Nasoenteric Feedings

A new technique for the anchoring of nasoenteric tube feedings is presented. The silicone rubber nasopharyngeal sling has increased the number of patients who can be nutritionally supported through the gastrointestinal route, without the probability of tube dislodgement. The sling, known as the bridle, has proven to be easily inserted and safe for prolonged periods of time. By permitting more patients to be tube fed and allowing their nutritional support to be rendered at home, the cost of this type of support can be decreased.

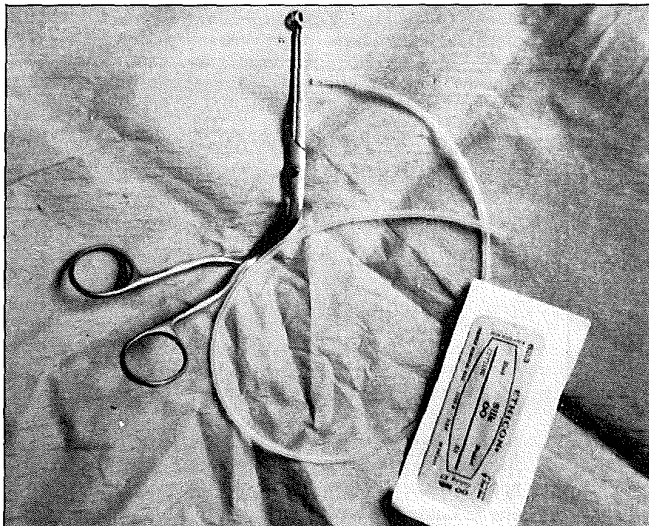


Figure 1: Materials for inserting the bridle.

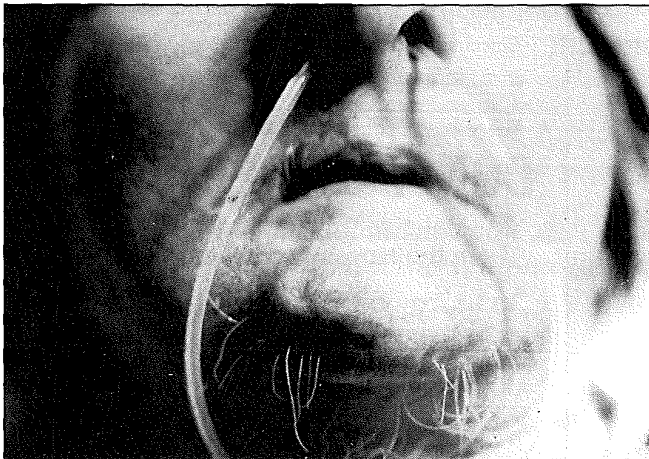

Figure 2: Silicone rubber tubing ends introduced into each nostril.

INTRODUCTION

Recent studies have indicated a great number of nutritional deficiencies may be found in hospitalized patients today.¹ The assessment of various nutritional abnormalities and their treatment with parenteral nutrition has significantly reduced the morbidity and mortality in these patients.² Metabolic abnormalities and catheter sepsis are associated complications of parenteral nutrition.³ Intravenous nutritional support is expensive and should be reserved for patients without sufficient gastrointestinal function to meet their nutritional requirements.

Proper techniques for administration of liquid formulas through nasoenteric tubes have been developed over the past decade.^{4,5} Use of the gastrointestinal tract is the safest, most economic and effective method of feeding a patient. The fact that a patient cannot or will not eat is not a reason to exclude the enteral route completely from consideration in nutritional support.⁶

The development of continuous pump feedings with lactose-free formula liquids has eliminated the majority of problems associated with bolus feedings such as cramping, diarrhea, distention, and dumping syndrome.⁷ The soft, small-bore feeding tubes with weighted tips have greatly enhanced tube placement and patient comfort and tolerance.⁸ The major problem encountered with these tubes is their ease of displacement. Many tubes have been removed by disoriented or confused patients; coughing and gagging can also displace these tubes. The aforementioned often will lead to the temporary or permanent termination of feeding. Until recently, the alternatives available for such patients were parenteral nutrition at higher cost and risks or a surgical procedure for the placement of an ostomy for feeding purposes.⁹

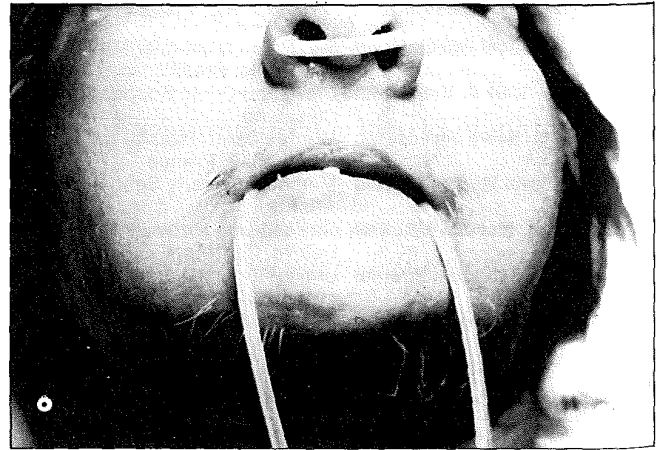


Figure 3: Both ends retrieved with forceps from the hypopharynx and brought out through the mouth.

The development of a nasopharyngeal sling for anchoring tubes, termed the *bridle* by Luther and Armstrong,¹⁰ has allowed nasoenteric nutritional support to be used with less chance of tube displacement. The bridle has increased the numbers of patients managed through the enteral route.

TECHNIQUE

The technique was first described in 1981.¹⁰ Since that time, we have used it with slight modifications. A minimal amount of equipment (an 18" length of small base silicone rubber tubing, a McGill or similar forceps, and 00 silk suture) is necessary to create the bridle (*Figure 1*).

After a thorough explanation of the procedure, the patient is allowed to sit up or the head of the bed is raised to 45°. The nostrils are checked for patency to establish which to use for inserting the feeding tube. Both nostrils are lubricated with a topical anesthetic. The hypopharynx is sprayed with a topical anesthetic to decrease gagging. One end of the silicone rubber tube is placed in one nostril gently pushing the tube tip down and back. The other end of the tube is placed in the opposite nasal passage in the same manner (*Figure 2*). When each limb has been advanced approximately 8", the patient is asked to open his mouth. Both ends of the tubing should be visible in the hypopharynx. The two free ends are grasped with the forceps, pulled out through the mouth (*Figure 3*), and sutured together (*Figure 4*). The loop of tubing across the columella is then pulled gently, bringing the tied ends of the

tube back to the nasopharynx and eventually to the posterior aspect of the nasal septum (*Figure 5*). One side of the loop is then advanced through one nasal passage while the other side is pulled, bringing the sutured ends through the nasal passage (*Figure 6*). Next, the tied ends are cut and the tubing is tied to itself allowing enough room between the loop and the septum to prevent pressure necrosis (*Figure 7*). Silk ties are placed in front and back of the knot to prevent slippage (*Figure 8*). The excess tubing is cut and the bridle is completed (*Figure 9*).

The enteric tube is then inserted through the preselected nasal passage and, once in place, anchored to the bridle by silk sutures and adhesive tape (*Figures 10 and 11*). Attempts at pulling the tube will result in gentle traction of the posterior aspect of the nasopharynx. Serious dislodgement by coughing, sneezing, or gagging is usually prevented by the fixed point of the tube.

CARE

The bridle and tube should be checked every eight hours. Tube position and bridle looseness should be noted. The tendency towards crusting can be avoided by use of topical antibiotic ointments. The adhesive tape should be replaced if loose or wet.

RESULTS

To date, we have employed this technique in 10 patients over the past year with encouraging results. The bridle has

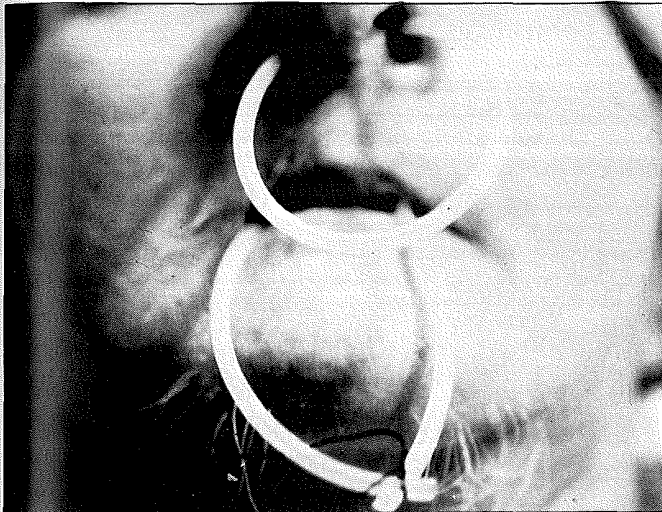


Figure 4: Ends sutured.

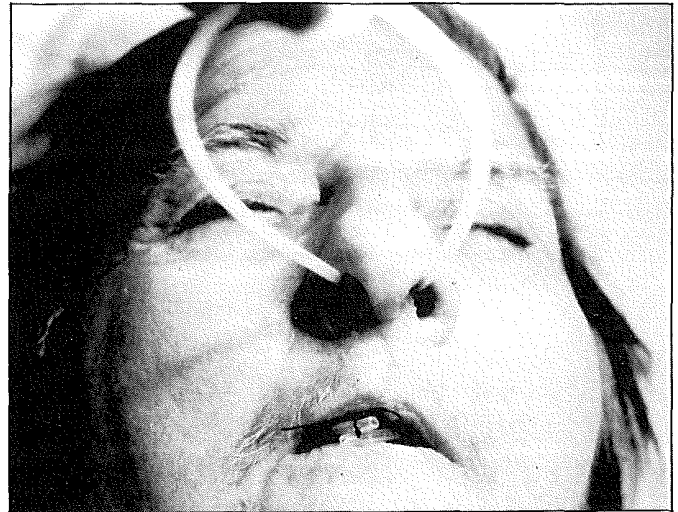

Figure 5: Sutured ends being pulled back to hypo- and nasopharynx.

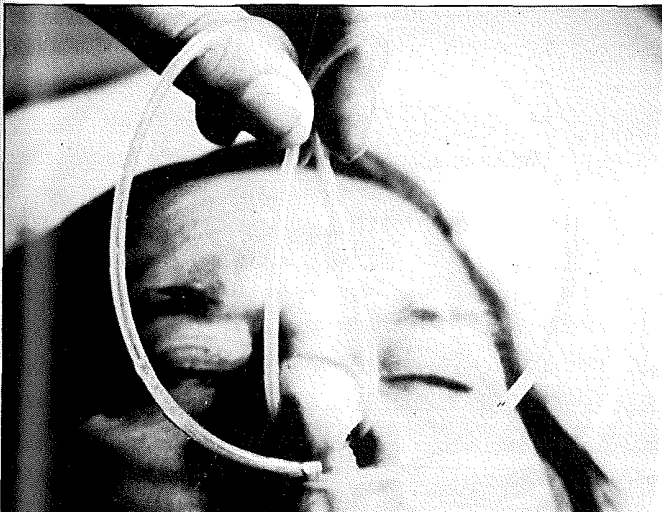


Figure 6: Sutured ends brought out through a nasal passage.

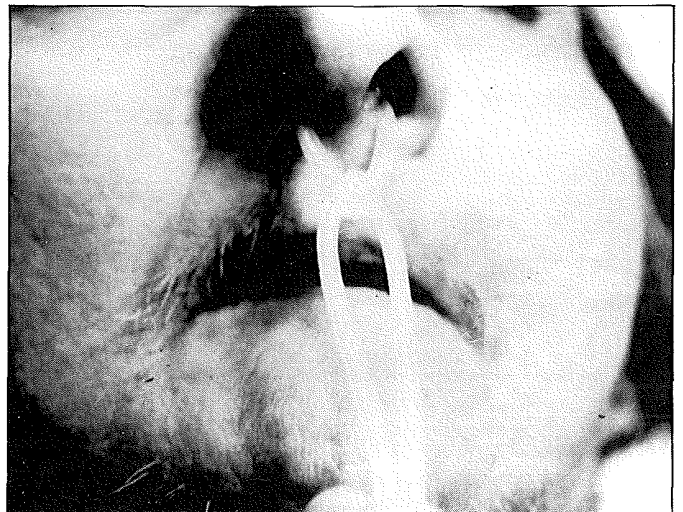

Figure 7: Tube tied to itself after cutting suture connecting ends.

allowed tube placement for periods up to three months and has facilitated the early discharge of patients enterally supported at home with further reduction in costs. One tube was pulled by a rather enterprising patient who managed to pull the tube distal to the anchoring suture in the bridle. Since institution of wrapping the tube and bridle with adhesive, this problem has not recurred.

Luther (personal communication) and Luther and Armstrong (in preparation)⁶ have employed the bridle on well over 500 patients and for as long as 11 months. Their rate of success and satisfaction has been similar to ours. The use of the technique has been extended to include nonfeeding tubes (i.e., nasogastric suction tubes) as well.

SUMMARY

Enteral nutrition has emerged as a safer, more economic and physiologic mode of nutritional support than the intravenous counterpart. In recent years, small, soft, pliable tubes for nasoenteric feedings have been developed, facilitating the use of the gastrointestinal tract in nutritional support. However, because of their increased flexibility, their dislodgement, particularly in uncooperative patients, has precluded their use.

The development of a nasopharyngeal anchoring sling known as the bridle has allowed for the increased use of the nasoenteric route of nutritional support. The technique is easily applied with minimal equipment. Results to date have

been gratifying. The technique has resulted in reduced costs, not only from the use of the enteral route, but also from the facilitation of home enteral nutritional support.

Acknowledgments. The authors wish to express their appreciation to Gae O. Decker and Cindy C. Stevenson for preparation and editorial assistance and Allen Dufour for photography.

REFERENCES

- 1. Butterworth CE. The skeleton in the hospital closet. *Nutr Today* pp. 4-8, March/April 1974.
- 2. Blackburn GL, Bistrian BR, et al. Nutritional and metabolic assessment of the hospitalized patient. *JPEN* 1(1):11-22, 1977.
- 3. Grant JP. *Handbook of Total Parenteral Nutrition*. Philadelphia: W.B. Saunders Co., 1980.
- 4. Barrocas A. ABC's of tube feeding. *La State Med Soc* 130(4):83-86, 1978.
- 5. Rombeau JL, Barot LR. Enteral nutrition therapy. *Surg Clin North Am* pp. 605-620, June 1981.
- 6. Heymsfield SB, Bethel RA, et al. Enteral hyperalimentation: An alternative to central venous hyperalimentation. *Ann Intern Med* 90:63-71, 1979.
- 7. Shils ME, Bloch AS, Chernoff R. Liquid formulas for oral and tube feedings. *JPEN* 1(2):89-96, 1977.
- 8. Dobbie RP, Hoffmeister JA. Continuous pump-tube enteric hyperalimentation. *Surg Gynecol Obstet* 143:273-276, 1976.
- 9. Torosian MH, Rombeau JL. Feeding by tube enterostomy. *Surg Gynecol Obstet* 150:918-927, 1980.
- 10. Luther RW, Armstrong CR. The bridle: A method of securing feeding tubes. Poster Session Presentation, American Society of Parenteral and Enteral Nutrition, Clinical Congress, New Orleans, LA, 1981.

NS3

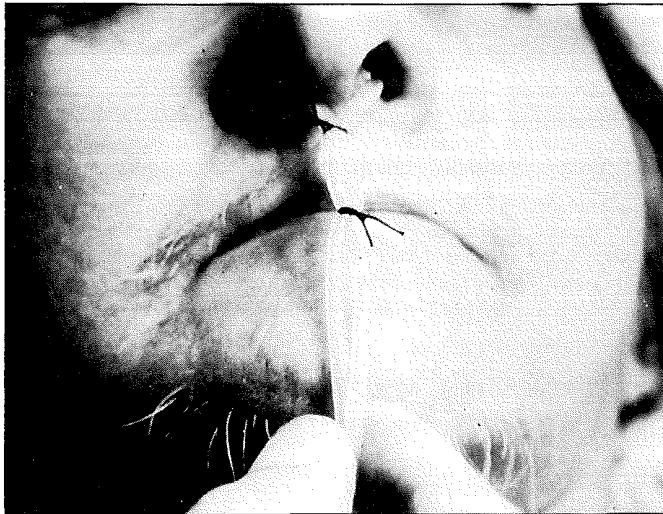

Figure 8: Ties applied in front and back of knot to prevent slippage.

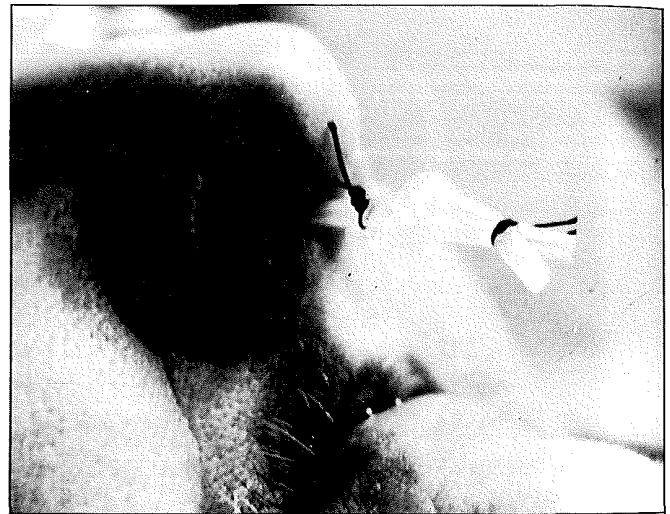


Figure 9: Bridle completed after cutting excess tubing.

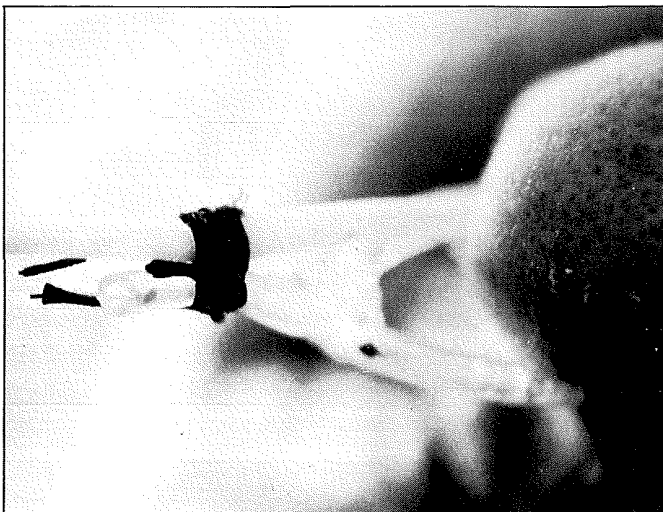


Figure 10: Feeding tube inserted and secured to bridle by silk ties.

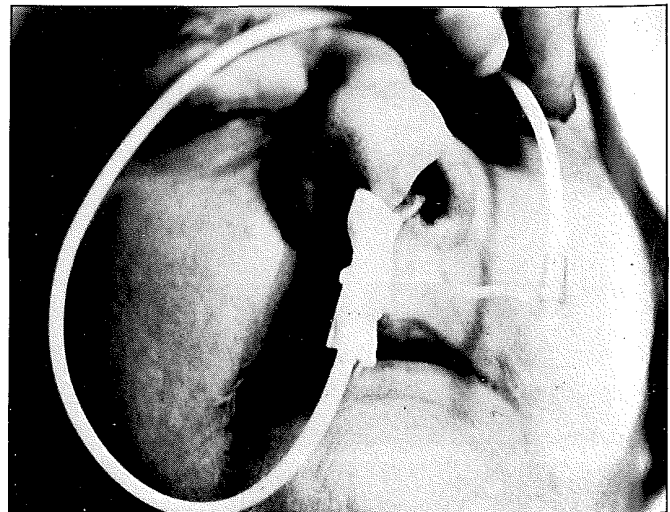


Figure 11: Adhesive tape applied for reinforcement.