

Photodynamic Therapy of Actinic Keratosis With Topical 5-Aminolevulinic Acid

A Pilot Dose-Ranging Study

Edward W. Jeffes, MD, PhD; Jerry L. McCullough, PhD; Gerald D. Weinstein, MD; Peter E. Fergin, MD; J. Stuart Nelson, MD, PhD; Toni F. Shull, RN; Karen R. Simpson, MD; Lisa M. Bukaty, MD; Wendy L. Hoffman, MD; Nora L. Fong, MD

Objective: To examine the safety and efficacy of photodynamic therapy using topical 5-aminolevulinic acid (ALA) and red light to treat actinic keratoses (AKs).

Design: Actinic keratoses were treated with topical ALA (concentrations of 0%, 10%, 20%, or 30%) under occlusion for 3 hours. Before photodynamic therapy, sites were examined for fluorescence. Sites were irradiated with an argon pumped dye laser (630 nm) at fluences of 10 to 150 J/cm².

Setting: Academic medical center.

Patients: Forty patients with 6 clinically typical, previously untreated AKs per patient.

Main Outcome Measure: Complete resolution and decrease in lesion area of the AK relative to baseline evaluated at weeks 1, 4, 8, and 16.

Results: Three hours after ALA administration, lesions

showed moderate red fluorescence. Cutaneous phototoxic effects, localized erythema and edema, peaked at 72 hours. Patients experienced mild burning and stinging during light exposure. Eight weeks after a single treatment using 30% ALA, there was total clearing of 91% of lesions on the face and scalp and 45% of lesions on the trunk and extremities. No significant differences were observed in clinical responses with treatment using 10%, 20%, or 30% ALA. All concentrations of ALA were more effective than treating AKs with vehicle and light.

Conclusions: Topical photodynamic therapy with ALA is an effective treatment of typical AKs. Complete clearing of nonhypertrophic AKs can be achieved with 10%, 20%, or 30% ALA that is easily tolerated by the patient. Lesions on the face and scalp are more effectively treated than lesions on the trunk and extremities. Hypertrophic AKs did not respond effectively.

Arch Dermatol. 1997;133:727-732

THE APPLICATION of 5-aminolevulinic acid (ALA) topically on skin leads to the accumulation of the endogenous photosensitizer protoporphyrin IX (Pp IX) in epidermal cells. Conversion of ALA to Pp IX is accomplished in normal and neoplastic skin cells by enzymes in the heme pathway. Protoporphyrin IX is characterized by a bright orange-red fluorescence and can be visualized in the skin when illuminated with a UV lamp. The tissue-specific phototoxic effects resulting from the topical administration of exogenous ALA provide a basis for using ALA-induced Pp IX for photodynamic therapy (PDT).¹

Photodynamic therapy using topical ALA has been shown efficacious in the treatment of various superficial epithelial cutaneous malignant

squamous cell carcinoma in situ (Bowen disease).^{2,3} Topical PDT with ALA also has been reported useful for the treatment of actinic keratoses (AKs) (solar keratoses),^{1,3} but these studies have been done in only a small number of patients and have used a fixed concentration of ALA (20%) with filtered or unfiltered visible light from a slide projector. The purpose of this dose-ranging study was to determine the safety and clinical efficacy of topical ALA (10%, 20%, or 30% ALA concentration) vs vehicle control with visible red light delivered by laser for the PDT of AKs.

RESULTS

Thirty-nine of the 40 patients completed

From the Department of Dermatology (Drs Jeffes, McCullough, Weinstein, Fergin, Nelson, Simpson, Bukaty, Hoffman, and Fong and Ms Shull) and the Beckman Laser Institute (Dr Nelson), University of California, Irvine, and the Veterans Affairs Medical Center, Long Beach, Calif.

Photodynamic Therapy of Actinic Keratosis With Topical 5-Aminolevulinic Acid

A Pilot Dose-Ranging Study

Edward W. Jeffes, MD, PhD; Jerry L. McCullough, PhD; Gerald D. Weinstein, MD; Peter E. Fergin, MD; J. Stuart Nelson, MD, PhD; Toni F. Shull, RN; Karen R. Simpson, MD; Lisa M. Bukaty, MD; Wendy L. Hoffman, MD; Nora L. Fong, MD

Objective: To examine the safety and efficacy of photodynamic therapy using topical 5-aminolevulinic acid (ALA) and red light to treat actinic keratoses (AKs).

Design: Actinic keratoses were treated with topical ALA (concentrations of 0%, 10%, 20%, or 30%) under occlusion for 3 hours. Before photodynamic therapy, sites were examined for fluorescence. Sites were irradiated with an argon pumped dye laser (630 nm) at fluences of 10 to 150 J/cm².

Setting: Academic medical center.

Patients: Forty patients with 6 clinically typical, previously untreated AKs per patient.

Main Outcome Measure: Complete resolution and decrease in lesion area of the AK relative to baseline evaluated at weeks 1, 4, 8, and 16.

Results: Three hours after ALA administration, lesions

showed moderate red fluorescence. Cutaneous phototoxic effects, localized erythema and edema, peaked at 72 hours. Patients experienced mild burning and stinging during light exposure. Eight weeks after a single treatment using 30% ALA, there was total clearing of 91% of lesions on the face and scalp and 45% of lesions on the trunk and extremities. No significant differences were observed in clinical responses with treatment using 10%, 20%, or 30% ALA. All concentrations of ALA were more effective than treating AKs with vehicle and light.

Conclusions: Topical photodynamic therapy with ALA is an effective treatment of typical AKs. Complete clearing of nonhypertrophic AKs can be achieved with 10%, 20%, or 30% ALA that is easily tolerated by the patient. Lesions on the face and scalp are more effectively treated than lesions on the trunk and extremities. Hypertrophic AKs did not respond effectively.

Arch Dermatol. 1997;133:727-732

THE APPLICATION of 5-aminolevulinic acid (ALA) topically on skin leads to the accumulation of the endogenous photosensitizer protoporphyrin IX (Pp IX) in epidermal cells. Conversion of ALA to Pp IX is accomplished in normal and neoplastic skin cells by enzymes in the heme pathway. Protoporphyrin IX is characterized by a bright orange-red fluorescence and can be visualized in the skin when illuminated with a UV lamp. The tissue-specific phototoxic effects resulting from the topical administration of exogenous ALA provide a basis for using ALA-induced Pp IX for photodynamic therapy (PDT).¹

Photodynamic therapy using topical ALA has been shown efficacious in the treatment of various superficial epithelial cutaneous malignant neoplasms

squamous cell carcinoma in situ (Bowen disease).^{2,3} Topical PDT with ALA also has been reported useful for the treatment of actinic keratoses (AKs) (solar keratoses),^{1,3} but these studies have been done in only a small number of patients and have used a fixed concentration of ALA (20%) with filtered or unfiltered visible light from a slide projector. The purpose of this dose-ranging study was to determine the safety and clinical efficacy of topical ALA (10%, 20%, or 30% ALA concentration) vs vehicle control with visible red light delivered by laser for the PDT of AKs.

RESULTS

Thirty-nine of the 40 patients completed the 16-week study. One patient voluntarily withdrew after 4 weeks because of a

From the Department of Dermatology (Drs Jeffes, McCullough, Weinstein, Fergin, Nelson, Simpson, Bukaty, Hoffman, and Fong and Ms Shull) and the Beckman Laser Institute (Dr Nelson), University of California, Irvine, and the Veterans Affairs Medical Center, Long Beach, Calif.

PATIENTS AND METHODS

PATIENT POPULATION

Forty patients (3 women and 37 men; median age, 70.5 years [range, 47-83 years]) with 6 AKs per patient were included in the study. A total of 218 lesions (grades 1-3) were evaluable at 8 weeks (grade 1, 78 lesions; grade 2, 118; and grade 3, 22). Of the 196 evaluable grade 1 and 2 lesions, 128 were on the trunk and extremities and 68 were on the face and scalp. Of the 22 grade 3 lesions, 21 were on the trunk and extremities and 1 was on the face or scalp. The largest diameter of the lesions ranged from 2 mm to 2.1 cm (median, 9 mm). Patients were excluded if they had received treatment of target AKs, or if they had used topical corticosteroids (previous 2 weeks); topical α -hydroxy acids or systemic corticosteroids (previous 4 weeks); or systemic retinoids, chemotherapeutic agents, or immunotherapy (previous 6 months). Pregnant or nursing women or patients with a history of cutaneous photosensitivity also were excluded. The study was approved by the University of California, Irvine, Human Subject Research Committee. Each patient received comprehensive information about the nature of the study and written informed consent was obtained before recruitment.

DRUG APPLICATION

Before application, ALA was admixed with a proprietary emollient vehicle (M55A, DUSA Pharmaceuticals Inc, Tarrytown, NY) to produce concentrations of 10%, 20%, and 30%. 5-Aminolevulinic acid test preparations at concentrations of 0%, 10%, 20%, or 30% were assigned to patients on a nonblinded basis. All 6 sites on a patient were treated with the same concentration of ALA. After applying ALA to target lesions and 10 to 20 mm of surrounding normal skin, test sites were covered with an adhesive, skin-colored, aluminized occlusive tape (3M Pharmaceuticals, St Paul, Minn) to prevent exposure to ambient light. Three hours after ALA application, immediately before assessment of fluorescence, the tape was removed and the area wiped to remove excess drug from the skin.

ASSESSMENT OF FLUORESCENCE

Immediately before light treatment, fluorescence of the treated lesions and surrounding normal skin was examined visually using a UV lamp (model B-100 AP, UVP, San Gabriel, Calif) containing a mercury flood lamp (model H-44 JM-100, Sylvania). Fluorescence intensity was scored as 0, none; 1, weak; 2, moderate; or 3, intense.

LIGHT TREATMENT

An argon pumped dye laser (model 920, Coherent Medical, Palo Alto, Calif) tuned to emit radiation at 630 ± 1 nm was used for the light treatments. A remote fiber splitter (model 1025, LaserTherapeutics, Buelton, Calif) permitted simultaneous laser irradiation of treatment sites. Each fiberoptic terminated in a microlens that focused the laser radiation onto a 2-cm-diameter circular field of uniform light intensity. Laser irradiation emanating from the fiber was

monitored with a power meter (model 210, Coherent Medical) before, during, and after treatment. The power density of the laser irradiation was gradually escalated (50, 100, 150 mW/cm²) in the first 10 patients to assess tolerance and safety. Because these patients easily tolerated all the power densities and there was no difference in patient tolerance at low and high power densities, the last 30 patients were treated using 150 mW/cm². Each of the 6 AKs on each patient were treated with 1 of the following fluences: 10, 25, 50, 75, 100, or 150 J/cm².

CLINICAL ASSESSMENT

Safety and clinical assessments were performed at baseline, immediately after PDT, and at 24 and 72 hours and at 1, 4, 8, and 16 weeks after PDT. Clinically typical AKs were selected by trained investigators as scaly erythematous papules and plaques devoid of cystic pores or a papillomatous surface (to exclude seborrheic keratosis and verrucae). Because having 6 lesions was required to enter the study, the patients had severe solar damage and had many AKs, of which only typical, easily evaluable lesions were selected. Lesions were clinically graded using criteria similar to those reported by Olsen et al,⁶ which were used to evaluate AKs treated with masoprocol cream. The criteria for each grade of AK are 1, easily seen, with slightly palpable hyperkeratosis (a thin AK); 2, easily seen and well-developed, easily palpated hyperkeratosis (typical well-developed AK); or 3, thick hyperkeratosis, evidence for thickened epidermis at margin of the AK, or both (hypertrophic or hyperkeratotic AK). The dimensions of the AK were measured and area ($\pi \times \frac{1}{2}$ length $\times \frac{1}{2}$ width) was calculated. Clinical response was defined as the percentage reduction of pretreatment lesion area and rated as complete response (CR), clear of palpable or visible lesion; partial response (PR), between 50% and 100% reduction in lesion area; or no response (NR), less than 50% reduction in lesion area. Lesions that did not have a CR at week 16 were treated with liquid nitrogen. Before and immediately after PDT and at each subsequent visit, treatment sites were evaluated for objective changes, including wheal-flare reactions (0, none; 1, minimal or barely perceptible; 2, moderate; and 3, severe), skin phototoxic effects (0, none; 1, minimal, asymptomatic erythema; 2, moderate erythema with pruritus or edema; 3, severe erythema with moderate to severe edema; and 4, skin ulceration). Subject assessment of patient discomfort from pain, burning and stinging, and itching was graded as 0, none; 1, slight; 2, moderate; 3, severe; or 4, very severe). Standard hematologic and biochemical laboratory values were evaluated at baseline and again at 1 week after PDT. Urine ALA was measured at baseline and at 24 hours after ALA application. Safety of the treatments was assessed by adverse events, the PDT response, and laboratory results.

The Student *t* test was used to compare quantitative variables. Summary statistics are expressed as mean \pm SD. Differences in clinical response between treatment variables were tested using the χ^2 test, or the Fisher test for small sample numbers. The Spearman rank order correlation was used to evaluate the relation between fluorescence, phototoxic effects, discomfort, and clinical response. Linear regression was used to evaluate the relation between response and light fluence administered.

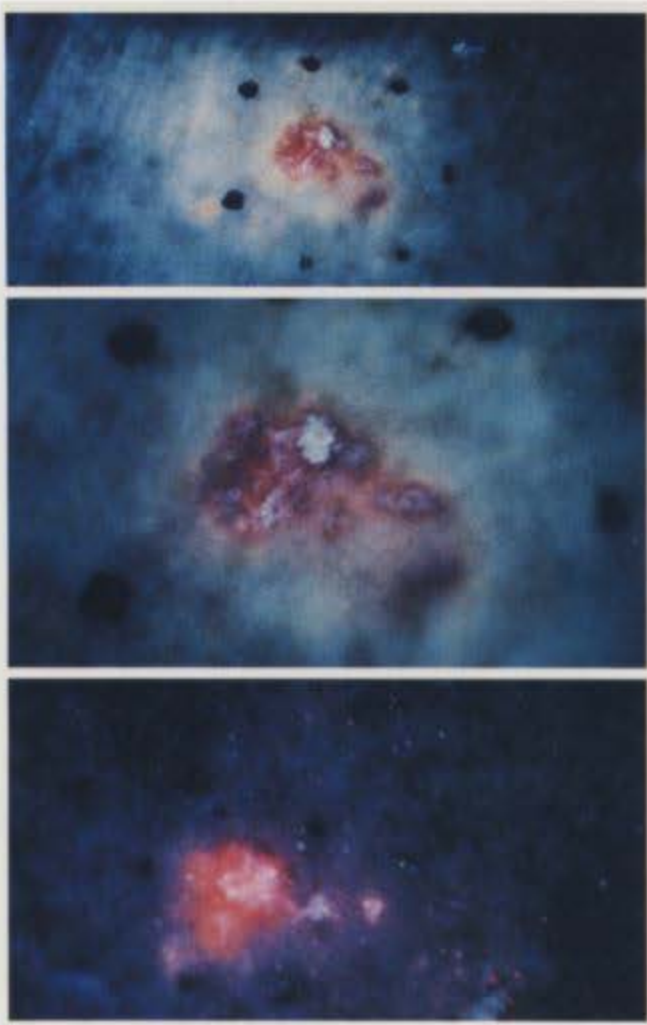


Figure 1. Actinic keratoses (AK) fluorescence after topical 5-aminolevulinic acid treatment. Top and center, Weak fluorescence of AK on extremity, with minimal fluorescence of adjacent normal skin. Bottom, More intense fluorescence of AK on scalp, with significant fluorescence of adjacent normal-appearing sun-damaged skin.

Pp IX FLUORESCENCE

Three hours of occluded application of ALA cream produced weak to moderate red fluorescence of grade 1 to 2 AKs at all concentrations of ALA. There was no significant difference between AKs treated with 10%, 20%, or 30% ALA. Thick, hyperkeratotic grade 3 AKs showed significantly less fluorescence. The surrounding normal-appearing sun-damaged skin treated with ALA showed a lesser degree of fluorescence. This selectivity was less pronounced on areas of the face and scalp, where both lesion and adjacent skin showed moderate fluorescence, with the AKs fluorescing brighter than the surrounding sun-damaged skin (**Figure 1**).

CLINICAL RESPONSE

The clinical response rate of grade 1 and 2 AKs and grade 3 AKs at 4, 8, and 16 weeks after PDT is shown in **Figure 2** and **Figure 3**, respectively. Maximum clinical improvement was obtained with treatment of grade 1 and 2 lesions with 30% ALA (61%, CR; 26%, PR). The

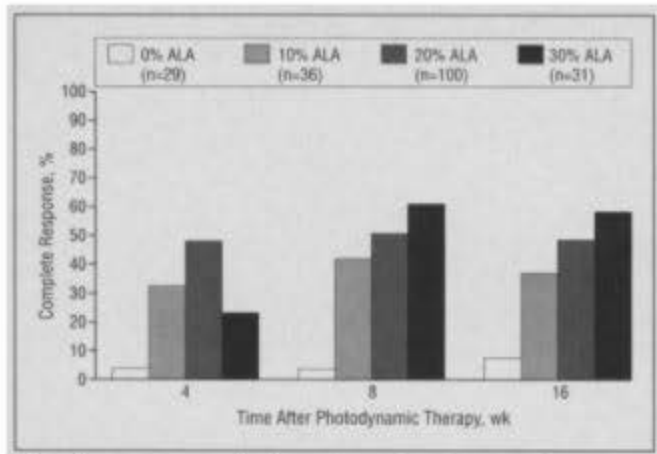


Figure 2. Response rate of all grade 1 and 2 (typical) actinic keratoses treated with 5-aminolevulinic acid (ALA) photodynamic therapy.

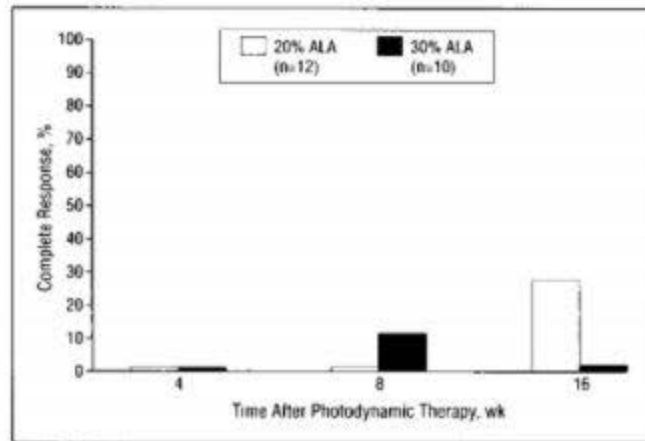


Figure 3. Response rate of all grade 3 (thick hyperkeratotic) actinic keratoses treated with 5-aminolevulinic acid (ALA) photodynamic therapy.

20%, or 30% ALA and light was significantly better than AKs treated with vehicle and light ($P < .001$). Thick, hyperkeratotic grade 3 AKs did not respond effectively to treatment with 20% or 30% ALA.

Actinic keratoses on the face and scalp responded significantly better to treatment with ALA and light compared with AKs treated on the trunk and extremities when 20% or 30% ALA was used to photosensitize the lesions ($P < .05$) (**Table 1**). The percentage of AKs on the face and scalp ($n=11$) treated with 30% ALA and light having a CR was 91%, while 45% of the AKs on the trunk and extremities ($n=20$) had a CR when treated identically ($P < .05$). The response distribution was not significantly different for AKs treated with 10% ALA and light when the face and scalp ($n=13$) was compared with trunk and extremities ($n=23$). The mean percentage improvement as measured by reduction in lesion area of face and scalp AKs was 90% to 99% vs 58% to 62% for trunk and extremity lesions treated with 10% to 30% ALA.

The CR rate of all grade 1 and 2 AKs treated with 20% ALA at fluences of 10 to 150 J/cm² is shown in **Figure 4**. Analysis of these data shows that a maximal CR rate was achieved at 10 J/cm², and this was not statistically different from the CR rate observed at 150 J/cm². Similarly, PDT with 20% ALA produced a maximum de-

Table 1. Clinical Responses of Face and Scalp vs Trunk and Extremities Actinic Keratoses (Grades 1 and 2) at 8 Weeks After Photodynamic Therapy*

% ALA	Face and Scalp			Trunk and Extremities		
	CR	PR	NR	CR	PR	NR
0†	0	6 (46)	7 (54)	1 (6)	3 (19)	12 (75)
10†	8 (61)	4 (31)	1 (8)	7 (30)	8 (35)	8 (35)
20‡	24 (78)	6 (19)	1 (3)	26 (38)	24 (35)	19 (27)
30‡	10 (91)	1 (9)	0	9 (45)	7 (35)	4 (20)

*ALA indicates 5-aminolevulinic acid; CR, complete response; PR, partial response; and NR, no response. Data are presented as total number of actinic keratosis sites treated with designated response, with the percentage of actinic keratosis sites treated with designated response in parentheses.

†Response distribution on face and scalp is not different from trunk and extremities (Fisher exact test, $P > .05$).

‡Response distribution on face and scalp shows a significantly improved response when compared with trunk and extremities (χ^2 , Fisher exact test; $P < .05$).

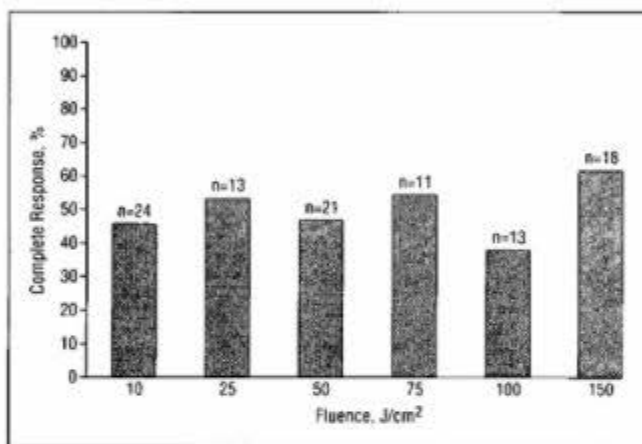


Figure 4. Complete response rate at 8 weeks of all grade 1 and 2 lesions treated with 20% 5-aminolevulinic acid (ALA) at fluences of 10 to 150 J/cm².

crease in effect with treatment at the higher fluences (10-150 J/cm²) (Student *t* test, $P > .05$). A further linear regression analysis showed a maximum effect on lesional area at 10 J/cm² that did not increase with fluences up to 150 J/cm² ($R^2=0.005$; $P=.48$). These data suggest that a maximal response had been reached at 10 J/cm² and that the response did not increase with higher light fluences up to 150 J/cm².

There was a significant correlation of AK fluorescence with improved clinical response (Table 2). There also was a significant correlation of fluorescence with increasing phototoxic effects on the AK and surrounding skin, but no correlation with subjective discomfort reported by the patient during light treatment.

The thicker grade 3 lesions did not respond well to PDT at any concentration of ALA compared with thinner typical grade 1 to 2 AKs. Because most of the grade 3 hypertrophic AKs treated in this study were on the extremities, we compared the response of grade 1 and 2 thin AKs with grade 3 thick AKs, limiting the AKs to the trunk and extremities treated with 20% ALA. Grade 1 and 2 AKs on the trunk and extremities decreased in area by

Table 2. Correlation of Fluorescence and Phototoxic Effects With Clinical Variables in Grades 1 and 2 Actinic Keratoses Treated With 20% 5-Aminolevulinic Acid Photodynamic Therapy

Comparison*	Spearman Rank Order Correlation	P
Fluorescence vs clinical response	0.35	<.001
Fluorescence vs phototoxicity	0.28	.005
Fluorescence vs discomfort	-0.02	.78
Phototoxicity vs clinical response	0.24	.02

*See the "Patients and Methods" section for a description of the clinical scales used.

decreased in area by 24% ± 24% (n=11), a significant difference ($P < .05$). A similar nonparametric analysis of the same data showed that grade 1 and 2 AKs had 26 CR and 40 PR and NR, and grade 3 AKs had 0 CR and 11 PR and NR, again a significant difference ($P < .02$, Fisher exact test). Thus, thick AKs on the trunk and extremities do not respond as well as typical thinner AKs in the same region of the body. There were not enough thick hypertrophic AKs treated on the face and scalp to do a similar analysis on this site.

CLINICAL EFFECTS OF PDT

There were mild phototoxic effects on the ALA-treated sites, which were manifest by localized erythema and edema that peaked 72 hours to 1 week after PDT and resolved by week 4 (Figure 5). In general, the phototoxic effects on the treated adjacent sun-damaged skin were much less than on the AKs. Photodynamic therapy resulted in superficial erosion of many of the AKs without eroding surrounding normal skin.

All patients experienced mild to moderate discomfort during light treatment (Figure 6), which was manifest by burning and stinging at the treatment site that started and was most severe with the beginning of irradiation, decreased during the irradiation, and stopped immediately when the irradiation was terminated. The treatment was well tolerated by most patients. There was no observable difference in patient discomfort during or after light treatment at power densities ranging from 25 to 150 mW/cm². All patients but 1 were able to complete the light treatments at all fluences. A wheal-and-flare reaction developed immediately after treatment in 14% of the treated lesions (mean intensity, 1.4; scale, 0-3). The cosmetic results of the PDT were excellent, with lesions clearing without persistent pigmentary alterations or scarring (Figure 7). There were no clinically significant abnormalities in laboratory tests and no significant changes from baseline of urine ALA measured at 24 hours.

COMMENT

The results of this study show that PDT with a single treatment using topical ALA and visible red light is highly effective for the treatment of typical AKs (grade 1 and 2 in this study). A single topical application of 30% ALA for

Explore Litigation Insights

Docket Alarm provides insights to develop a more informed litigation strategy and the peace of mind of knowing you're on top of things.

Real-Time Litigation Alerts



Keep your litigation team up-to-date with **real-time alerts** and advanced team management tools built for the enterprise, all while greatly reducing PACER spend.

Our comprehensive service means we can handle Federal, State, and Administrative courts across the country.

Advanced Docket Research



With over 230 million records, Docket Alarm's cloud-native docket research platform finds what other services can't. Coverage includes Federal, State, plus PTAB, TTAB, ITC and NLRB decisions, all in one place.

Identify arguments that have been successful in the past with full text, pinpoint searching. Link to case law cited within any court document via Fastcase.

Analytics At Your Fingertips



Learn what happened the last time a particular judge, opposing counsel or company faced cases similar to yours.

Advanced out-of-the-box PTAB and TTAB analytics are always at your fingertips.

API

Docket Alarm offers a powerful API (application programming interface) to developers that want to integrate case filings into their apps.

LAW FIRMS

Build custom dashboards for your attorneys and clients with live data direct from the court.

Automate many repetitive legal tasks like conflict checks, document management, and marketing.

FINANCIAL INSTITUTIONS

Litigation and bankruptcy checks for companies and debtors.

E-DISCOVERY AND LEGAL VENDORS

Sync your system to PACER to automate legal marketing.